

## RELATIONSHIP OF THE EXPRESSION OF MDR1 GENE PRODUCT IN HEPATO CELLULAR CARCINOMA TO INVASION AND METASTASIS

Kong Xianbing 孔宪炳    Yang Zukui 杨祖奎    Fang Kaixian 方开先

Department of Surgery, The First Affiliated Hospital, Chongqing University of medical Sciences, 400016

**Objective:** To study the relationship of the expression of P-glycoprotein (P-gp) in hepatocellular carcinoma (HCC) to invasion and intrahepatic metastasis. **Methods:** Surgical samples of 47 patients with HCC were investigated using immunohistochemical method in combination with computer-imaging analytic technique. **Results:** In HCC, anti-P-gp immunostaining was mainly localized in the cellular membrane. A significantly higher positive percentage of P-gp expression was observed in HCC tissues than normal liver tissues ( $P<0.01$ ). HCCs with intrahepatic metastasis had a significantly higher P-gp expression level than those without intrahepatic metastasis ( $P<0.01$ ). The expression level of P-gp in HCCs with invasion was significantly higher than that in HCCs without invasion ( $P<0.05$ ). **Conclusion:** P-gp may play an important role in the invasion and intrahepatic metastasis of HCC. P-gp expression level in tumor correlates the progression of HCC.

**Key word:** HCC, P-gp, Invasion, Metastasis, Image analysis, Immunohistochemistry

### INTRODUCTION

P-glycoprotein (P-gp), the product of the multidrug-resistance (MDR1) gene, is a 170Kda membrane protein responsible for pumping lipophilic drugs out of tumor cells at the expense of ATP.<sup>1</sup> Over-expression of the MDR1 gene and P-gp has been

demonstrated in clinical tumor samples of a variety of histological type.<sup>2,3</sup> Although P-gp expression in cancer might be closely related to clinical drug resistance, other biological functions of P-gp expression have not been clarified yet. It has also been reported that P-gp may possibly be associated with carcinogenesis, tumor progression and differentiation.<sup>4</sup> This study aimed to investigate P-gp expression in HCC and to assess the relationship between P-gp expression level and invasion and intrahepatic metastasis of HCC by using immunohistochemical method in combination with computer-imaging analytic technique.

### MATERIALS AND METHODS

#### Patients and Specimens

The specimens were obtained by surgical resection from 47 patients with HCC from June 1996 to July 1997. There were 39 men and 8 women. Ages ranged from 25 to 74 years (mean age 49 years). None of them received chemotherapy preoperatively. Of the 47 tumors, 33(70%) were large HCCs (diameter>5cm), and the remaining 14(30%) were small HCCs (diameter  $\leq$  5cm). 19(40%) and 12(26%) were accompanied with invasion and intrahepatic metastasis, respectively. Invasion included involvement of portal veins tumor emboli, invasion of capsule and presence of satellite nodules. 11 normal liver tissues were gained at surgery from patients without chronic liver disease as control.

Accepted July 23, 1998

## Immunohistochemical stainings for P-gp

Specimens were fixed in formalin and embedded in paraffin. Serial sections were prepared at 4  $\mu$ m thickness. Immunohistochemical examination was performed by the streptavidin-biotin-complex(SABC) method using monoclonal antibody JSB-1(Boehringer mannheim). The negative control was processed by substituting PBS for the primary antibody. The positive control was a breast cancer sample shown to express P-gp by SABC method.

## Quantitative Analysis

Immunoprecipitates were analyzed using an Axiotron microscope (Zeiss, Germany) and a 3CCD camera (JVC, Japan), and then processed by an image analysis system (IBAS, Kontron, Germany). Positive unit (PU) was tested and calculated as described previously.<sup>5</sup> PU represents P-gp expression level. Five times were performed at random in a section.

## Statistical Analysis

PU of P-gp was expressed as  $\bar{x} \pm s$ . The data were analyzed statistically by means of Student's *t*-test. Statistical significance was defined as a two-sided *P* value of *P*<0.05.

## RESULTS

### Positive Expression of P-gp in HCC and Normal Liver Tissues

P-gp-positive cells were not distributed uniformly. The intensity of immunoreactivity was also variable. The staining was mainly observed in the cellular membrane (Figure 1). In normal liver, P-gp was present on the bile canalicular surface of hepatocytes and the luminal surface of epithelial cells of the bile duct. In P-gp-positive HCC, the staining was observed on the contact surface between tumor cells, resembling the canalicular staining pattern. P-gp expression was found in 72.3%(34/47) of HCC tissues, whereas it was seen in 27.2%(3/11) of normal liver tissues (*P*<0.01).

### P-gp Expression Level (PU) in Relation to Invasion and Intrahepatic Metastasis of HCC

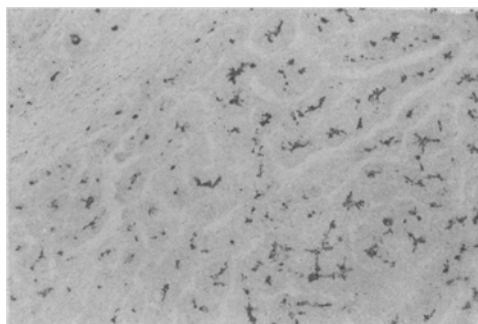


Fig 1. HCC tissues, showing strong staining of P-gp positive reaction (PU value 45.71). SABC,  $\times 100$

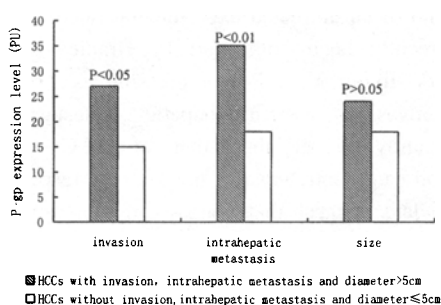


Fig 2. Relationship of P-gp expression level in HCC to invasion and intrahepatic metastasis.

The expression level of P-gp in HCCs with invasion was significantly higher than that in HCCs without invasion (*P*<0.05). HCCs with intrahepatic metastasis had a significantly higher P-gp expression level than those without metastasis (*P*<0.01). On the other hand, there was no significant difference in P-gp expression level between large HCCs and small HCCs (*P*>0.05)(Figure 2).

## DISCUSSION

Normal hepatocytes exclusively express P-gp on the biliary canalicular surface, and some physiological function of P-gp as a transporter from hepatocytes to bile canaliculi has been suggested. P-gp expression in HCC resembled that of normal hepatocytes, and was detected on the biliary or luminal surface of the tumor cells as shown in this study and other reports.<sup>6</sup> In the current study, all patients had no previous history of anticancer chemotherapy. Therefore, this high

incidence of P-gp expression of HCC might be brought about intrinsically, and not by cancer chemotherapy. Our results indicated that positive percentage of P-gp expression in HCC tissues was significantly higher than that in normal liver tissues, which suggest that P-gp were also modulated under some conditions such as carcinogenesis and tumor progression.<sup>4</sup>

Recent researches have revealed that P-gp expression was associated with the ability of cancer cells to invade and metastasise. A study in colon cancer indicated increased numbers of P-gp positive cells at the invading edges of tumors of high metastasis potential.<sup>7</sup> This association between level of expression of P-glycoprotein and the metastatic potential of an untreated experimental rat liver tumor has recently been confirmed by Bradley and co-workers.<sup>8</sup> In our study, P-gp expression level of HCCs with invasion and intrahepatic metastasis was significantly higher than that of HCCs without invasion and intrahepatic metastasis, respectively. These data suggest that P-gp expression level was closely related to invasion and intrahepatic metastasis of HCC, and might be mainly controlled by the biological character of human cancer, not by induction of cancer chemotherapy. There was no significant difference in P-gp expression level between large HCCs and small HCCs, which suggest that P-gp expression may play an important role in the growth and development of HCC on certain conditions, and reached a high level while HCC having a tendency to invade and metastasise.

In spite of the fact that P-gp may have biological functions in cancer cells in addition to those involved in cytotoxic drug transport, up to now the mechanism of the relationship of P-gp over-expression in patient's tumors to tumor progression has not been understood fully. Generally, the processes of tumor invasion and metastasis involve complex changes in cell-cell and cell-substratum interactions.<sup>9</sup> P-gp probably plays central roles in these processes.<sup>10</sup> Although the adhesion profiles of P-gp have not been examined in detail, several recent observations raised the possibility that P-gp may influence cell-cell adhesion and enhanced tumor cell motility, as a result of this, the processes involved in the dissemination of HCC

including the formation and propagation of tumor emboli within portal veins and intrahepatic metastasis.<sup>11</sup> Therefore, P-gp over-expression was suppressed with a reverse agents of MDR1 gene or P-gp modulators, which might be a new approaches to prevent and inhibit invasion and metastasis of HCC.

## REFERENCES

1. Goldstein LJ. MDR gene expression in solid tumors. *Eur J Cancer* 1996; 32A: 1039.
2. Chou YY, Cheng AL, Hsu HC. Expression of P-glycoprotein and P<sup>53</sup> in advanced hepatocellular carcinoma treated by single agent chemotherapy: Clinical correlation. *J Gastroenterol Hepatol* 1997; 12: 569.
3. Jain V, Das SN, Luthra K, et al. Differential expression of multidrug resistance gene product, P-glycoprotein, in normal dysplastic and malignant oral mucosa in india. *Int J Cancer* 1997; 74: 128.
4. Chin KV, Ueda K, Pastan I, et al. Modulation of activity of the promoter on the human MDR<sub>1</sub> gene by Ras and P<sup>53</sup>. *Science* 1992; 255: 459.
5. Shen H. Study on the quantitative method of immunohistochemistry(3). *Chin J Histo-cytochem* 1995; 4: 89.
6. Ishiiki K, Nakano A, Ito M, et al. P-glycoprotein expression in hepatocellular carcinoma. *J Surg Oncol* 1993; 52: 21.
7. Sinicrope F, Hart J, Brasitus TA, et al. Relationship of P-glycoprotein and carcinoembryonic antigen expression in human colon carcinoma to local invasion, DNA ploidy, and disease relapse. *Cancer* 1994; 74: 2908.
8. Bradley G, Sharma R, Ling V, et al. P-glycoprotein expression during tumor progression in rat liver. *Cancer Res* 1992; 52: 5154.
9. Ruoslahti E, Giancotti FG. Integrins and tumor cells dissemination. *Cancer Cells* 1989; 1: 119.
10. Nicolson GL. Organ Specificity of tumor metastasis role of preferential adhesion, invasion and growth of malignant cells at specific secondary sites. *Cancer Metastasis Rev* 1988; 7: 143.
11. Kaye SB. P-glycoprotein and drug resistance-time for reappraisal? *Br J Cancer* 1993; 67: 641.