

T-CELL RECEPTOR GENE REARRANGEMENT ANALYSIS IN THE PRIMARY CUTANEOUS T-CELL LYMPHOMA*

Qiu Bingsen 邱丙森 Wang Ping¹ 王平 Gao Hongyang² 高红阳
Shang Yifei² 尚易非 Xu Liangzhong³ 许良中

Dermatopathologic Research Laboratory, Institute of Dermatology, Huashan Hospital;

²*Department of Biophysics;* ³*Department of Pathology, Tumor Hospital, Shanghai Medical University, Shanghai 200040, ¹Nanking Railway Medical College, Nanking 210009*

Object: The present paper is to evaluate the significance of T-cell receptor (TCR) gene rearrangements in primary cutaneous T-cell lymphomas (PCTCL) as detected by analysis of Southern Blot (SBA) and polymerase chain reaction (PCR). **Patients and Methods:** Skin specimens and peripheral blood samples were taken from 44 patients with PCTCL, including 30 patients with mycosis fungoides (MF), 2 patients with Sezary's syndrome (SS), and 12 patients with PCTCL other than MF and SS (PNCTCL). 11 patients with a presumptive diagnosis of MF, 23 patients with lymphoproliferative dermatoses including lymphomatoid papulosis (LyP) and 8 patients with benign cutaneous lymphoid infiltrates were simultaneously studied by the amplification of junctional V (variable)-J (joining) sequences of the rearranged TCR γ genes by PCR(TCR γ PCR) and the analysis of TCR β -chain genes by SBA(TCR β SBA) for detection of clonal gene rearrangements (GR). One lymph node specimen of a case with MF IIA was also detected by TCR γ PCR and TCR β SBA. **Results:** In MF, GR were detected by TCR γ PCR and TCR β SBA in 83.3-85.7% and 66.7%-71.4% of skin specimens of cases IIA-IIB and in 57.1%-70.0% and 14.3%-10.0% of those of cases IA-IB, respectively. GR were seen in 66.7%-71.4% and 33.3%-43.0.% of blood samples of cases IIA-IIB, and 42.9%-40.0% and 0-10.0% of those of cases IA-IB, respectively. GR was confirmed by TCR γ PCR

and TCR β SBA in one lymph node showing dermatopathic lymphadenopathy of a case with MF IIA. In 11 patients of clinically suspected MF, GR were present in skin specimens of 5 cases (45.4%) and in blood samples of 3 cases (27.3%) by TCR γ PCR. In PNCTCL, GR were found in 9 skin specimens (90.0%) from 10 patients detected by TCR γ PCR and in 6 skin specimens (75.0%) from 8 patients detected by TCR β SBA. GR were also seen in 6 blood samples (72.8%) from 11 patients detected by TCR γ PCR, and in 7 blood samples (70.0%) from 10 patients by TCR β SBA. In SS and LyP, GR were detected by TCR γ PCR and TCR β SBA in each of the two skin specimens of two cases with LyP and in each of the two blood samples of two cases with SS. GR were seen in one skin specimen of one case with SS and one blood sample of one case with LyP detected by TCR γ PCR. **Conclusions:** This study demonstrated that TCR γ PCR is a rapid, more sensitive tool than TCR β SBA, can be used in the analysis of T-cell clonality in skin, lymph node and blood samples of patients with PCTCL and indicated that this method forms a useful supplement to other methods for diagnosis of early and suspected MF, confirmation of PNCTCL and determination of extracutaneous involvement of lymph node and blood.

Key words: Primary cutaneous T-cell lymphoma, PCR, T-cell receptor, Gene rearrangement.

Accepted July 2, 1997

* This project was supported by the National Natural Science Foundation of China (No. 39070781).

Primary cutaneous T-cell lymphomas (PCTCL) represent a group of neoplastic clonal T-cell lympho-

proliferating disorders that clinically originate in the skin, comprising more than 80% of cutaneous malignant lymphomas (CML). They show considerable variability in clinical presentation, histology, immunophenotype and prognosis.¹ PCTCL have a broad spectrum of entities, the most frequent of which are mycosis fungoides (MF) and Sezary's syndrome (SS), constituting 1/3 of CML.² Recently, it was found that PCTCL other than MF and SS (PNCTCL) were not uncommon and represented approximately 30% of all the cutaneous T-cell lymphomas (CTCL) excluding lymphomatoid papulosis (LyP); the majority (90%) of these CTCL were large cell lymphomas.¹

Weiss et al. were the first to apply molecular analysis of T-cell receptor (TCR) gene rearrangements (GR) to a lymphoproliferative disorders of the skin and described clonal rearrangements in the skin and lymph nodes of patients with MF.³ Subsequently, the molecular analysis of lymphocytic infiltrates of the skin has greatly expanded to include a wide variety of dermatologic entities. Clonal T-cell population had been detected in such diseases as CTCL, adult T-cell leukemia/lymphoma, pagetoid reticulosis, LyP, pityriasis lichenoides et varioliformis acuta (PLEVA), cutaneous lymphoid hyperplasia (CLH)⁴ and actinic retinoid (AR)⁵ and small plaque parapsoriasis (SPP).⁶ There are some or close relationships between PCTCL and these T-cell lymphoproliferating dermatoses (LPD). Although no clonal T-cell population are detected in certain benign cutaneous reactive lymphocytic infiltrates (BCRLI) such as Jessner-Kan-of lymphocytic infiltrates, phenytoin-induced pseudolymphoma, lichen planus (LP), allergic contact dermatitis, pityriasis rosea and chronic eczema,⁴ PCTCL could be difficultly differentiated from them clinically and histologically. In addition, in some instances it is also difficult to differentiate between PNCTCL and cutaneous B-cell lymphomas and other types of CML. Molecular diagnosis of cutaneous infiltrates refers to the use of molecular biologic techniques to molecularly characterized lymphocytic infiltrates and it plays a helpful role in the clinical diagnostic evaluation of patients.⁴ In this study we attempt to evaluate the detection of clonal T-cell GR in cutaneous lymphocytic infiltrates by polymerase chain reaction (PCR) and analysis of Southern blotting (SBA).

MATERIALS AND METHODS

Patients

Forty-four patients with PCTCL, including 30 patients with MF, two with SS and 12 with PNCTCL, were diagnosed by histology and immunohistology, and confirmed by long-term follow-up (1–30 years, mean 5 years). They were divided into groups according to the TNM classification, namely, IA, 7 patients of MF IB, 10 (MF), IIA, 12 (MF, 7, PNCTCL -5), IIB, 13 (MF 6, PNCTCL 7) and III, 2 (SS). Two patients had LyP (one patient preceding with MF). 11 patients were suspected to be MF clinically or histologically. 23 patients with LPD included 4 with PLEVA, 7 with SPP, 6 with CLH and 4 with AR. As negative controls eight patients with BCRLI, including 6 patients with LP, 1 with profound lupus erythematosus (PLE), and 1 with discoid lupus erythematosus (DLE), were also investigated. Basically, one skin biopsy specimen from involved skin and 5–10 ml heparinized peripheral blood were obtained from each patient. One clinically enlarged superficial lymph node biopsy specimen was also available from a patient with MF IIA. The skin and lymph node specimens were snap frozen and stored in liquid nitrogen. The peripheral blood mononuclear cells were prepared by Ficoll-Hypaque gradient centrifugation and stored in liquid nitrogen.

Methods

All the skin and lymph node specimens and peripheral blood samples were simultaneously studied by TCR γ PCR and TCR β SBA for detection of GR.

DNA Isolation

High-molecular-weight DNA was prepared by standard procedures.

Clonal TCR β GRSBA

Ten μ g of DNA from each sample were digested separately to completion with restriction enzymes, *Bam*HI, *Eco*RI and *Hind*III (Shanghai Branch, Sino-American Biotechnology Co.). Digested DNA was size-fractionated by electrophoresis on a 0.8% agarose-gel. The DNA was transferred onto nitrocellulose paper, as described by Southern. The paper-bound DNA was then hybridized with ³²P-labeled DNA fragment specific for human TCR β for

24 h. After hybridization, the filters were washed at room temperature in $2 \times \text{SSC}$ ($1 \times \text{SSC}$ is 150 nmol sodium chloride, 17 nmol sodium citrate, pH 7.0) and 0.5% sodium dodecyl sulfate (SDS). The process was repeated at 50°C in $1 \times \text{SSC}$ and 0.1% SDS, and exposed to Kodak AR 5 X-ray film with double densifying screen at -70°C for 48 h. The TCR probe (a 0.77 Kb Pst-1 fragment) was kindly provided by Professor Gu Jianren, hybridizing to both constant regions of the TCR.

Clonal TCR γ GRPCR

The PCR reaction mixture contained 2 μl (50 pmol) of primer T10/20 or C10/20, template DNA 2–10 μl (1 μg), Taq polymerase 3 μl (3 μg), 2 mmol/L of four kinds of dNTP 5 μl , standard buffer solution 5 μl and 0.1 mol/L MgCl_2 0.5 μl in a volume of 25 μl . Typically, 35 cycles of amplification were performed where each cycle consisted of 30 s at 94°C (first cycle, 10 min), 45 s at 55°C and 45 s at 72°C (last

cycle 500 s at 72°C). Extreme care was taken before amplification to avoid contamination from extraneous DNA including use of plugged pipette tips for all sample manipulation. For analysis, 10 μl aliquots of PCR products were then electrophoresed through 2% regular agarose, stained with ethidium bromide for 5–10 min, and then visualized with ultraviolet light. A distinct and sharp band indicates GR. The primers were synthesized by Shanghai Biocytological Institute, Chinese Science Academy, and their sequences were T10/20 mer: 5'TCTTCCAACCTTGGGAAGGGAGA3' and C10/20 mer: 5'CCCTCTATTACCTTGGAAATG3', respectively.

RESULTS

Criteria of Judgement

Two hybridizing banding patterns were observed (Figure 1, 2).

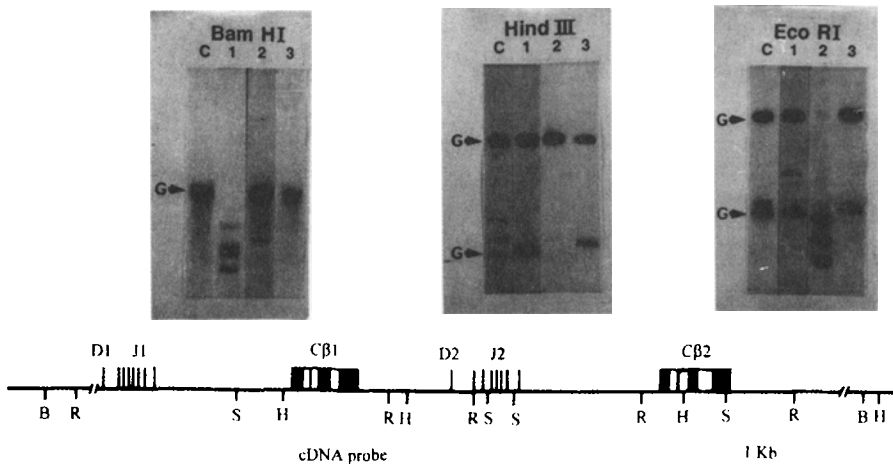


Fig. 1. The results of Southern blot analysis of skin tissue DNA from patients with MF III (1) and SS (2), and peripheral blood DNA from SS (3) and controls (C) after hybridization with a probe (with 0.77 Kb Pst-1 fragment, CB1 TCR cDNA) (indicated by the bar), which cross-hybridizes with CB2 (B: *Bam*HI; H: *Hind*III; E: *Eco*RI). G indicates germline.

TCR β GRSBA

Germline Bands

Germline fragments after chromosomal DNA

digested separately by *Bam*HI, *Eco*RI and *Hind*III showed 11 Kb, 4.2 Kb, 24 Kb and 7.2 Kb, 4.1 Kb, 3.7 Kb, respectively. The varieties of partial lanes were mainly caused by clonal abortion, incomplete digestion of restriction enzymes and partial degradation of

chromosomal DNA.

Rearranged Bands

These are markers of clonal TCR β GR. There were individual heterogeneity of sizes and numbers of rearranged bands.

TCR γ GRPCR:

Clonal TCR γ GR were defined by amplified bands of 400 bp and there were also appearance of dimers of primers and formation of polyclonal T-cell smear.

MF

The results are shown in Table 1.

In the superficial lymph node specimen of one case with MF IIA, TCR γ GR and TCR β GR were seen, although the lesion was interpreted as dermatopathic lymphadenopathy by histological and immunopheno-

typic criteria.

Clinically Suspected MF

In 11 patients suspected of having MF, TCR γ GR were seen in skin specimens of 5 cases (45.4%) and blood samples of 3 cases (27.3%).

SS PCR and SBA

Analysis of blood from two patients with SS showed TCR γ GR and TCR β GR in both and revealed the same clonal GR pattern, which was also found in a biopsy from the erythroderma skin of one case.

PNCTCL

TCRGR are shown in Table 2.

Some LPD

The results are shown in Table 3.

Table 1. Gene rearrangements in 30 patients with MF

| Stage | No. of cases | TCR γ GRPCR specimens | | | | TCR β GRSBA specimens* | | | |
|-------|--------------|------------------------------|------|----|------|------------------------------|------|---|------|
| | | E | % | B | % | E | % | B | % |
| IA | 7 | 4 | 57.1 | 3 | 42.9 | 1 | 14.3 | 0 | |
| IB | 10 | 7 | 70.0 | 4 | 40.0 | 1 | 10.0 | 1 | 10.0 |
| IIA | 6 | 5 | 83.3 | 4 | 66.7 | 4 | 66.7 | 2 | 33.3 |
| IIB | 7 | 6 | 85.7 | 5 | 71.4 | 5 | 71.4 | 3 | 43.0 |
| Total | 30.0 | 22 | 70.3 | 16 | 53.3 | 11 | 36.7 | 6 | 20.0 |

E: skin B: blood *No. of cases and percentages

Table 2. Gene rearrangements in 12 patients with PNCTCL

| Samples | Methods | No. of cases | TCRGR* | | | | | | | |
|---------|---------|--------------|--------|-----|-----|------|-----|-----|---|------|
| | | | | | IIA | | IIB | | | |
| | | | IIA | IIB | | | IIA | IIB | | |
| | | | | | % | | % | | % | |
| E | PCR | 10 | 5 | 5 | 9 | 90.0 | 5 | 100 | 4 | 80.0 |
| | SBA | 8 | 5 | 3 | 6 | 75.0 | 4 | 80 | 2 | 66.6 |
| B | PCR | 11 | 5 | 6 | 8 | 72.8 | 5 | 100 | 3 | 50.0 |
| | SBA | 10 | 5 | 5 | 7 | 70.0 | 4 | 80 | 3 | 60.0 |

E: skin B: blood *No. of cases and percentages

Table 3. Gene rearrangements in 23 patients with LPD

| Diagnosis | No. of cases | TCR γ GRPCR specimens* | | | | TCR β GRSBA specimens* | | |
|-----------|--------------|-------------------------------|-----|---|----|------------------------------|-----|---|
| | | E | % | B | % | E | % | B |
| LyP | 2 | 2 | 100 | 1 | 50 | 2 | 100 | 0 |
| PLEVA | 4 | 1 | 25 | 1 | 25 | 1 | 25 | 0 |
| CLH | 6 | 1 | 17 | 0 | | 0 | | 0 |
| SPP | 7 | 1 | 14 | 0 | | 0 | | 0 |
| AR | 4 | 0 | | 0 | | 0 | | 0 |

E: skin B: blood *No. of cases and percentages

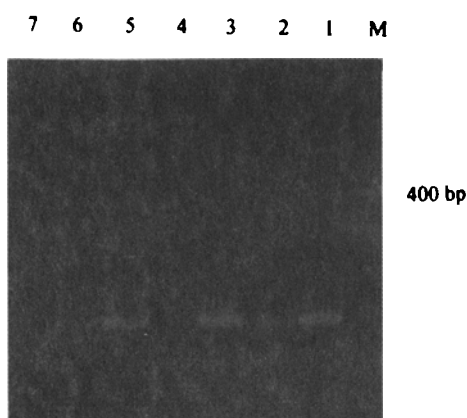


Fig. 2. Except for cases 4 and 7, amplified products after TCR γ GR in cases 1, 2, 3, 5 and 6 with PCTCL. M: PCR marker (from Sino-American Company).

Some BCRLI

No TCRGR was found in all the cases with BCRLI.

DISCUSSION

MF

Early Diagnosis

It was rarely difficult to provide established plaque-stage MF on the combination of clinical,

histological, and immunophenotypical data. Molecular detection of GR may usually confirm diagnosis. Our results of the skin samples taken from 13 patients with MFI studied separately by TCR γ GR and TCR β GR showed that the percentages of GR were 83%–85% and 66.6%–71.4% respectively, corresponding to the data reported.^{7,8} Diagnostic problems are evident in early stages, in which the distinction between patch-stage MF and benign inflammatory dermatoses may be difficult. Although TCR GRSBA usually fails to show monoclonal gene rearrangements in patch stage MF, TCR γ GRPCR are considered to be a helpful tool for the early diagnosis of MF. Our results of the skin specimens taken from 17 patients with MF I studied separately by TCR β GRSBA and TCR γ GRPCR showed that the percentages of GR were 10.0%–14% and 57.1%–70% respectively. It is noteworthy that we had also obtained TCR γ GR in skin specimens of 5 cases (45%) from 11 patients suspected of having MF. Just as emphasized by Wolff-Sneedorff, et al.⁹ for the patients who clinically seemed to be MF but not diagnosed histologically TCR γ GRPCR should be performed.

Extraneous Involvements

Lymph Nodes

Determination of the status of lymph nodes is particularly important for the clinical evaluation of patients with MF. In attempts to document early involvement by MF in lymph nodes showing dermatopathic lymphadenopathy, investigators have used a number of special diagnostic procedures, including electron microscopy, cytogenetic analysis, DNA cytophotometry and immunophenotyping, sometimes in various combinations. All of these methods have

disadvantages.³ Molecular detection of rearranged TCR genes could confirm early involvement of MF in lymph nodes showing dermatopathic lymphadenopathy. We also had found this by detecting TCRGR in a case with MF IIA by PCR and SBA. However, so-called dermatopathic nodes have also been shown to be involved by monoclonal disease in 50% of cases. Therefore, the 10 clinicopathologic findings should be combined in the interpretation of early involvement of MF in lymph nodes.

Peripheral Blood

The percentages of TCRGR in our cases with MF IIA and IIB studied by PCR and SBA were 66.7%–71.4% and 33.3%–43% respectively. The results are not corresponding to the data reported. It may probably be related to the long duration of illness and staging. Except for one case with MF IIA, the lymph nodes in the remaining patients, especially in late stage, no detection of TCRGR was performed.

PNCTCL

Wolff-Sneedorff, et al. had analyzed skin and blood samples from nine patients with large cell CTCL by SBA, GR could be detected in both samples of five cases. GR were seen in the skin lesions in only half of these patients.⁹ Our results showed that GR were seen in 9 skin samples from 10 patients detected by PCR and 6 skin samples from 8 patients determined by SBA. GR were found in 8 blood samples from 11 patients detected by PCR and 7 blood samples from 10 patients by SBA. In this group of CTCL, some were more complicated than those seen in MF as suggested by Wolff-Sneedorff, et al.⁹

SS, LyP and Some LPD

Our results were similar to that of the literature reviewed by Slater.¹⁰

REFERENCES

1. Williemze R, Beljaards RC, Meijer. Classification of primary cutaneous T-cell lymphomas. *Histopathol* 1994; 24:405.
2. Burg G, Dummer R, Kerl H. Classification of cutaneous lymphomas. In: Burg G, Kerl H, Thiers B, eds. *Cutaneous Lymphoma Dermatol Clinics*. 1994; 12:213.
3. Weiss I.M, Hu E, Wood GS, et al. Clonal rearrangements of T-cell receptor genes in mycosis fungoides and dermatopathic lymphadenopathy. *N Engl J Med* 1985; 313:539.
4. Weinberg GM, Rook AH, Lessin SR. Molecular diagnosis of lymphocytic infiltrates. *Arch Dermatol* 1993; 129:1491.
5. 堂阪直子, 岡野弘子, 藤四真由美, ほか. Actinic reticuloid における皮膚浸潤にリンパ球の monoclonality の検討. 山田瑞穂主編. *皮膚のリンフォマ VIII*. 日本: 浜松. 1989; p22.
6. Haeffner AC, Smoller BR, Zepter K, et al. Differentiation and clonality of lesional lymphocytes in small plaque parapsoriasis. *Arch Dermatol* 1995; 131:321.
7. Bachelez H, Bioul L, Flageul B, et al. Detection of clonal T-cell receptor γ gene rearrangements with the use of the polymerase chain reaction in cutaneous lesions of mycosis fungoides and Sezary's syndrome. *Arch Dermatol* 1995; 131:1027.
8. Mielke V, Staib G, Boehncke WH, et al. Clonal disease in early cutaneous T-cell lymphoma. In: Burg G, Kerl H, Thiers B, eds. *Cutaneous Lymphoma Dermatol Clinics*. 1994; 12:351.
9. Wolff-Sneedorff A, Ralfkiaer E, Thomsen K, et al. Analysis of T-cell receptor- β -chain genes by Southern blotting in known and suspected cutaneous T-cell lymphoma. *Clin Exp Dermatol* 1995; 20:115.
10. Slater DN. Review of investigative diagnostic techniques for cutaneous lymphomas. *Seminar Dermatol* 1994; 13:166.