

## AN IMMUNOHISTOCHEMICAL STUDY OF NEUROEN- DOCRINE CELLS IN COLONIC CARCINOMA

Yu Jiyao<sup>1</sup> 虞积耀 Li Yandong<sup>2</sup> 李燕东 Wang Jialing<sup>1</sup> 王嘉玲

1 General Hospital of The Navy, Beijing, 100037

2 Beijing Fuxing Hospital

Seventy-four cases of colonic cancer were studied by immunohistochemistry using anti-Chromogranin A, gastrin, somatostatin, serotonin, glucagon and human chorionic gonadotropin (HCG) to observe the neuroendocrine cell in colonic cancer. It was found that 27 of 74 colonic carcinoma showed variable extent of CgA staining (36.5%). Glucagon and HCG was differently the most frequent in hormone antigens in colonic cancer and in metastatic lymph nodes. The endocrine positive colonic carcinomas are more frequent in poorly-differentiated than in well-differentiated ( $P<0.05$ ). It suggests that there were different NE cells producing different hormones in colonic cancer. Different hormones may act on different types of colonic cancer.

**Key words:** Neuroendocrine cell, Colonic cancer, Immunohistochemistry.

It is well known that the gastrointestinal tract acts as an endocrine organ. The colonic carcinoma contained endocrine-differentiated cancer cells as its integral tumor component. In the present study, various neuroendocrine (NE) cells were examined by immunohistochemical staining and its biological

significance was discussed.

### MATERIALS AND METHODS

Seventy-four cases resected colon with colonic carcinoma and five non-cancer colon obtained at necropsy for normal control were collected during the age of the patients ranged from 29 to 78 years (mean, 51.6). Man was 55, female was 19. The specimens had been fixed in neutral formalin and block embedded in paraffin. Four-five blocks were taken for each specimen including tumor and regional lymph node. A serial 10 sections were cut from each blocks in 5  $\mu$  m. Hematoxylin and eosin, staining were carried out. The immunohistochemical staining was visualized with the ABC procedure (ABC kit, K355, DACO USA). The primary antibodies and positive control listed in table 1. Peroxidase was revealed using diaminobenzidine tetrahydrochloride (DAB). Control of the specificity of the immunoreaction was performed by incubating consecutive sections with noimmune serum instead of the primary antiserum or with the specific antiserum preabsorbed with an excess of respective antigens.

Statistical significance was determined using the chi-square test for the measurements of NE cells of colonic carcinoma.

Accepted February 12, 1996

Table 1. List of antibodies used in the present study

Code	Antigens	Antibody type	Working dilution	Positive control
A430	Chromogranin A(CgA)	P	1: 400	pancreas islet
A586	Gastrin (GAST)	P	1: 300	gastric antrum
A566	Somatostatin (SS)	P	1: 400	pancreas islet
A758	Serotonin (5-HT)	M	1: 20	gastric antrum
A565	Glucagon (GLU)	P	1: 800	pancreas islet
A571	HCG	P	1: 800	placenta villus

P: polyclonal; M: monoclonal

## RESULTS

Twenty-seven of 74 colonic carcinoma showed variable extent of CgA staining (36.5%), which were observed by immunohistochemical methods with 5 types of hormonal antibodies. Only two of these expressed CgA without any hormonal expression; 10 containing one type hormone; 8 two types; of 3 three types; 2 four types. Thirteen of the 27 cases contained more than one hormone. The 5 hormones found in colonic cancer were as follows: 5-HT (10 cases), HCG (8 cases), GLU (15 cases), SS (3 cases), GAST (7 cases). These positive cells were triangular, flat, or cylindrical in shape, with characteristic positive staining at the infranuclear spaces (Figure 1).

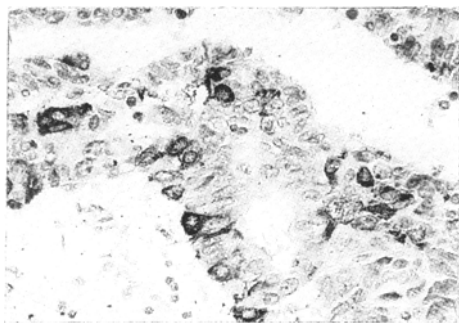


Fig. 1. The NE cells in colonic tubular adenocarcinoma. Glucagon immunohistochemical staining, ABC method  $\times 450$

The positive staining varied considerably in each NE cell. These NE cells were found scattered over (Figure 2) and penetrating the deeper layers of the colon, or restricted within a small area of tumor. The 74 cases

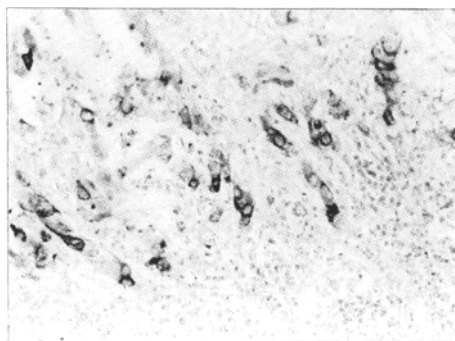


Fig 2. The NE cells in colonic poor-differentiated adenocarcinoma. CgA immunohistochemical staining, ABC method  $\times 450$ .

colonic adenocarcinoma were divided into two groups including well-differentiated (tubular-52 cases) and poor-differentiated (mucinous, 10 cases; signet cell carcinoma, 5 cases; poor-differentiated adenocarcinomas, 3 cases). NE cell and the histological types are in Figure 3. There were more NE cells in

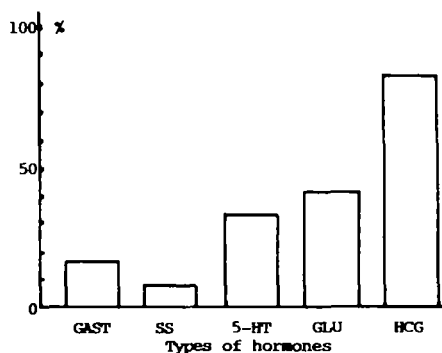


Fig 3. The rate of different of hormone types in NE cell positive metastasis in lymph node.

first group (16/53, 30.7%) than in the second one (11/22, 50%,  $P < 0.01$ ). In 35 of 74 cases metastasis in lymph nodes were found 12 of 27 cases (44.4%) in colonic cancer with NE cells positive and 23 of 47 (48.9) with NE cells negative showed the metastasis in lymph node ( $P > 0.05$ ). HCG positive cells were found in 8 cases with lymph nodes metastasis and a frequency higher than other hormones, (Figure 4.  $P < 0.001$ ).

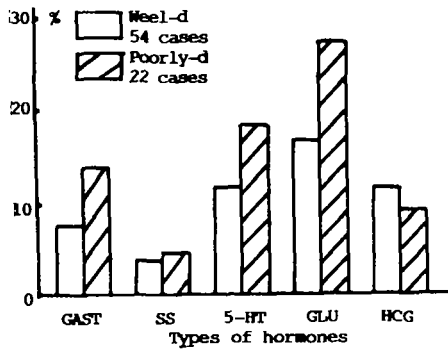


Fig 4. The positive rate of different of hormone types in two groups of colonic carcinoma.

WELL-D: well-differentiated colonic carcinoma  
 POOR-D: poor-differentiated colonic carcinoma

## DISCUSSION

The presence of NE cells in carcinoma of gastrointestinal tract has long been established.<sup>1</sup> Endocrine differentiation is not a rare phenomenon in conventional gastric carcinoma (3.1% — 53.3%). But the report about NE cell in colonic cancer was rare. Using immunohistochemical staining we found 27 of 74 cases of colonic carcinomas (36.5%) contained NE cells. Glucagon was the most frequent hormone antigens. Our study suggested that endocrine positive carcinomas are more frequent in poorly-differentiated than in well-differentiated ( $P < 0.05$ ), GLU was more frequent in well-differentiated colonic cancers.

Some peptides can play act as growth factors stimulating on proliferation of gastrointestinal cancer cells, such as GAST,<sup>2,3</sup> GLU,<sup>4</sup> CT and BOM.<sup>5</sup> Production of some hormones might be an event in the course of dedifferentiation, such as HCG<sup>6</sup> which was not found in normal colonic mucosa. It was reported that patients with gastric cancer and high levels of

HCG in the serum or a high density of HCG-positive cells in tumor tissue had a poor prognosis. Other hormones, such as SS, can be inhibitory to the growth of tumor cell. Somatostatin has been found to inhibit the growth of several experimental cancers, many of which are endocrine dependent. The presence of receptors for gastrointestinal hormones such as GAST, VIP,<sup>7</sup> has been reported on gastrointestinal cancer cell lines. Some reported<sup>8</sup> suggested paracrine or autocrine modes of action of biologically active peptide factors released by NE cells. Such *in vitro* evidence of tumor cell growth regulation by autocrine and paracrine mechanisms led us to presume the existence of a paracrine interaction between NE cells in colonic cancer. Our findings suggest some hormones, such as Glucagon and HCG may act as promoters of tumor growth and able to stimulate the growth of colonic cancer.

In conclusion, our observation suggested that there were different NE cells producing different hormones in colonic cancer. Different hormones may act on different types of colonic cancer. Further investigation is required to elucidate the significance of relations between colonic carcinoma and hormonal substances.

## REFERENCES

1. Hayashi H, Ooi A, Nakanishi I. Biological And Clinicopathological Significance of Endocrine Differentiation of Gastric adenocarcinoma Evaluated by Double Immunohistochemical Labeling for Chromogranin A And Bromodeoxyuridine. *Jpn J Clin Oncol* 1990; 20 (4): 339.
2. Stamm B, Sarmaiani P. Coincidence of Fundic Glandular Hyperplasia And Hormonal Content of Endocrine Cells in Gastric Cancer. *Histopathology* 1989; 63 (5): 354.
3. Smith JP, Solomon TE. Effects of Gastrin, Proglumide And Somatostatin on Growth of Human Colon Cancer. *Gastroenterology* 1988; 95(8): 1541.
4. Ito H, Yokozaki H, Hata J, Mandai K, et al. Glicentin-containing Cells in Intestinal Metaplasia, Adenoma And Carcinoma of The Stomach. *Virchows arch pathol anat* 1984; 404(1): 17.
5. Cuttitta F, Carney DN, Mulshine J. Bombesinlike Peptides Can Function As Autocrine Growth Factors in Human Small Cell Lung Cancer. *Nature* 1985; 316

- (4): 823.
6. Camp E, Palacin A, Benasco C, et al. Human chorionic Gonadotropin in Colorectal Carcinoma. *Cancer* 1987; 59(9): 1611.
  7. Laburthe M, roussert M, Chevalier G, et al. Vasoactive Intestinal Polypeptide Control of Cyclic 3': 5' -Monophosphatase Levels in Seven Human Colorectal Adenocarcinoma Cell Lines in Culture. *Cancer Res* 40(12): 2529.
  8. Dawson IMP. Diffuse endocrine And Neuroendocrine Cell Tumours in Anthony PP, Macsween RNM, eds. *Recent Advances Histopathology*. Edinburgh: churchill Livingstone. 1993: 111-128.