

THE CLINICOPATHOLOGICAL AND PROGNOSTIC STUDY ON 42 CASES WITH CARDIAC TUMOR

Wang Xuzhou 王绪洲 Liang Sitai 梁思泰 Wang Min* 王敏 Li Suying 李素英

Department of Pathology, The Affiliated Hospital, Shandong Medical University, Jinan, 250012

* Western Hospital of Jinan Railroad Bureau, 250117

Objective: To analyze the relation between the pathological changes and the clinical manifestations and the prognosis of cardiac tumors through the pathological study on 42 cases with cardiac tumor, in order to improve the knowledge of the tumors, to make early diagnosis and to raise the curative ratio.

Materials and Methods: 42 confirmed cardiac tumors of our department were selected, among which 41 was surgical specimen and 1 was autopsy. The study was performed by using the common and special histochemical staining.

Results: 41 is primary and 1 is secondary which is a metastazed hepatocellular carcinoma. In the primary ones, 39 (95.1%) is benign, including myxoma, fibroma, rhabdomyoma and pericardial cyst, while 2 (4.9%) is malignant, including neurolemmafibrosarcoma and malignant mesothelioma. In the myxomas, female patients occupy 75%, 91.7% exists in the left atrium and every one has got a peduncle adhesive to the fossa ovalis or adjacency of the atrial septum.

Conclusions: The results of the pathological and prognostic study shows cardiac tumors are quite different from the tumors in other sites, i.e., even benign ones could cause fatal hemodynamic disturbance. Hence early diagnosis and early operation are necessary and if in such instance, the prognosis of most of the benign ones would be good. But the prognosis of the malignant tumors is worst. The myxomas are different from the organized thrombi in heart cavity. And also the criteria of diagnosis and differential diagnosis are discussed.

Key words: Cardiac tumor, Myxoma, Fibroma, Rhabdomyoma, Neurolemmafibrosarcoma, Malignant Mesothelioma, Pathology

Cardiac tumor is a kind of ones rarely found. Missed and misdiagnosis are easily occurred just because of no prominent differences of clinical symptoms with other diseases of heart so that some patients would lose the chance of treatment, especially in the areas with worse medical condition. We carried the clinicopathological analysis of 42 cardiac tumors, diagnosed by surgical pathology and autopsy, in order to improve the knowledge of cardiac tumor and raise the ratio of early diagnosis and cure.

MATERIALS AND METHODS

Forty-two cases with cardiac tumor were collected from the department of Pathology, the Affiliated Hospital, Shandong Medical University and from 1971 to 1995, which consisted of 41 cases of operation specimen and 1 autopsy. The specimens were formalin-fixed (10% concentration), paraffin-embedded and stained with hematoxin and eosin. Particular histochemical stainings as PAS, Alcian Blue, Masson's VG and modified Gordon-Sweets method were done in some cases.

RESULTS

Accepted February 14, 1996

Myxoma

36 cases totally, 33 of which were found in the left atrium while only 3 in the right. All of the tumors were singular with a peduncle in the fossa ovalis or adjacency of the atrial septum. Gross: the peduncle was 0.6 — 1.4 cm in length with abundant collagen fibers. The largest was 9 × 7 × 4 cm while the smallest was 3.7 × 3.2 × 2.4 cm. Spherical or polypoid or botryoid, slightly greyish red, smooth, semitransparent, tremellose, soft and brittle. Microscopically: scanty cells were polygonal or spindle-shaped and singly or focally distributed in loose stroma rich in mucus and capillary (Figure 1). strongly positive in alcian blue and weakly positive in PAS. The surface was covered with columnar or flat epithelial cells.

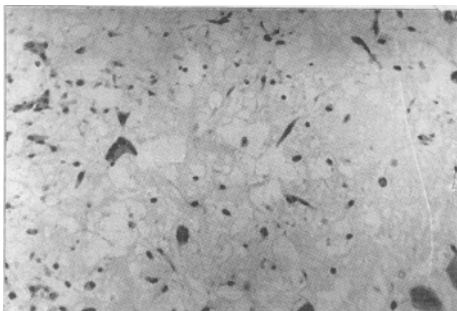


Fig 1. Cardiac Myxoma: Scanty cells were polygonal or spindle-shaped and singly or focally distributed with much mucus in stroma. H.E 20X

Fibroma

1 case only in the posterior wall and atrial septum of the left atrium. Gross: 88.5g in weight and 12.5 × 11 × 9 cm in dimension. The cutting surface was greyish red and tenacious. The surface was covered with numerous papillaries in variable size (Figure 2). Microscopically: the tumor was composed of fibrocytes and collagen fibers in interlaced arrangement, most of which had gone hyalinization. VG staining showed that abundant collagen fibers were red in interlaced and whorling arrangement.

Cardiac Rhabdomyoma

1 case only in the left ventricle wall. Gross:

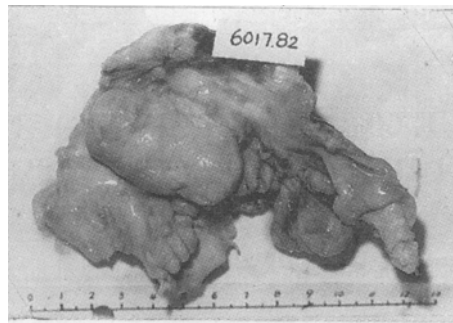


Fig 2. Fibroma of left Atrium: 88.5g in weight and 12.5 × 11 × 9 cm in size. Papillary-like surface.

nodular and clear demarcation. The cutting surface was greyish red and tenacious. Microscopically: in its spongy structure, the ramose or polygonal cells have got cross striation in the cytoplasm with prominent nucleoli and nuclei in the center, around which cytoplasm was in loose network forming the characteristic and diagnostic spider-like cell (Figure 3). PAS staining showed positive granules. The stroma was rich in blood vessels. The normal adjacent muscles of heart was compressed to atrophy, sharply demarcated.

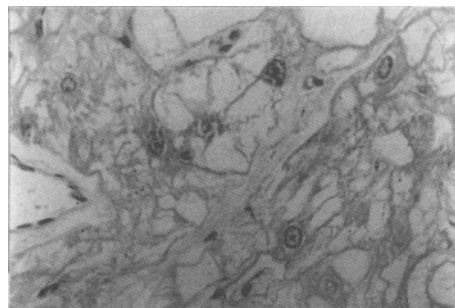


Fig 3. Cardiac Rhabdomyoma: Spongy structure, spider-like cell with loose network cytoplasm around the nucleus. H.E 40X

Pericardial Syst

1 case in the right cardiodiaphragmatic angle of pericardium. Gross: 6 × 6 × 5 cm in dimension, smooth and cystic. The cyst wall was soft and 0.3 cm in thickness, the inner side of which was smooth, too.

The cyst contained clear fluid. Microscopically: the wall was composed of loose connective tissue and lined with a layer of mesothelial cells.

Neurolemmofibrosarcoma

1 case in the right pericardium. Gross: Soft and nodular with the size of 18× 12× 10 cm. The cutting surface was fish-flesh appearance, accompanied with focal hemorrhages, necrosis and cyst-forming. Microscopically: The densely packed cells were oval or short spindle with marked atypia, arranged in fasciculi, whorls with slightly palisading of nuclei. Mitosis was numerous (Figure 4).

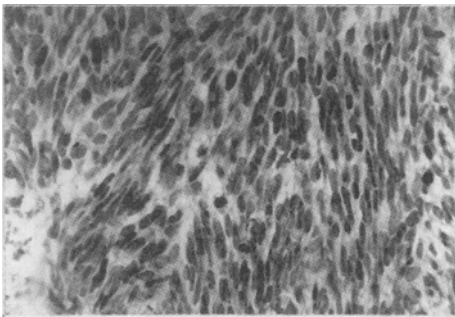


Fig 4. Pericardial neurolemmofibrosarcoma: dense, short spindle and hyperchromatic cells are arranged in fascicles, whorls and slightly palisading of nuclei. Pathologic mitosis is numerous. H.E 40X

Malignant Mesothelioma

1 case in the pericardium. Gross: The tumor surrounded the heart with diffuse thickness, nodular and a dimension of 13× 7× 1.5 cm. The cutting surface was greyish red and hard. Microscopically: the marked atypical cells were arranged in solid nest or incomplete glands. Between the nests much short spindle cells with marked atypia were densely packed, representing the structure of fibrosarcoma (Figure 5). Modified Gordon-Sweets staining showed that reticular fibers were distributed between the nests in some areas or between the tumor cells in other areas.

Metastatic Hepatocellular Carcinoma of Heart

1 case of autopsy, which showed that a round,

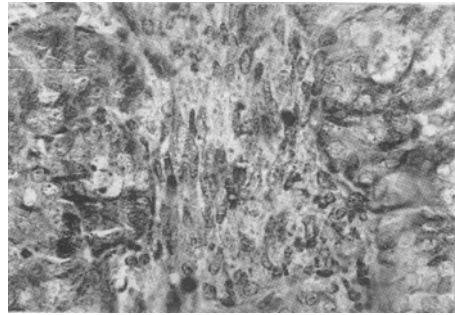


Fig 5. Malignant mesothelioma of pericardium: The tumor cells with marked atypia are arranged in nest-like structure or diffuse fibrosarcoma-like ones. H.E 40X

hard and greyish white mass existed in the right atrium with a size of 5× 3.5× 2.5 cm (Figure 6). In the middle part of the right lobe of liver a mass, 12 cm in diameter, was found accompanied with hepatocirrhosis. Microscopically: The tumor cells were polygonal, markedly atypical and arranged in cords with formation of blood sinusoids. The autopsy diagnosis was that primary hepatocellular carcinoma had invaded into the hepatic veins of the right lobe, inferior vena cava and the right atrium, accompanied the portal cirrhosis.

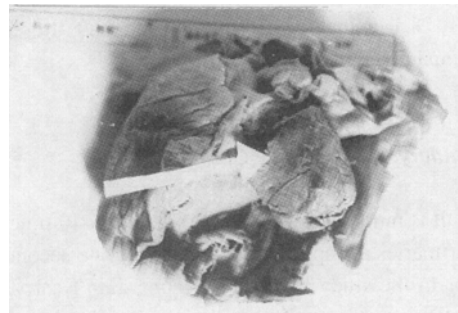

Fig 6. Metastatic hepatocellular carcinoma of right atrium: a hard, greyish white and round mass with 5× 3.5× 2.5 cm in size.

DISCUSSION

Classification And Incidence of Cardiac Tumor

Primary Cardiac Tumor

It is very seldom found, only occupying 0.09% of all the cardiac operations as reported.¹ Of these 41 primary ones, 38 (92.7%) was found in the heart proper and 3 (7.3%) in the pericardium while 39 (95.1%) was benign, including myxoma, fibroma, rhabdomyoma and pericardial cyst and 2 (4.9%) malignant, including neurolemmafibrosarcoma and malignant mesothelioma. In the cardiac tumors, the benign ones are the commonest.

36 (87.9%) of the cases was myxoma which was the commonest of the primaries, occupied 92.3% of the benign and occurred mostly in the females (75%), and 33 (91.7%) of which was found mostly in the left atrium and only 3 (8.3%) in the right, attached to the fossa ovalis of the atrial septum. It is a true tumor originated from the undifferentiated mesenchymal cells of the endocardium.^{2,3} The incidence of it and the one of it in the left atrium only had a very little variation between this study and the statistical results of China,⁴ which is very high, 88.9% and 90.4% respectively.

A more seldom found tumor is cardiac fibroma, which is mostly in children and probably originated from the fibroblasts of endocardium or myocardium.^{5,6} The diameter as reported is usually 3-7 cm.^{1,7} The one case in this study was a 47-year-old male, who had got a rarely giant fibroma, 88.5g in weight and 12.5×11×9 cm in dimension.

Another rare tumor is cardiac rhabdomyoma, which is also mainly in children and half the cases accompanied with nodular cirrhosis.⁸

Secondary Or Metastatic Cardiac Tumor

It is much more frequently found, 16-40 times of the primaries as reported.¹ There's only one secondary tumor in the study because surgeons didn't carry out operations on the patients with metastasis and autopsy couldn't be done once the patients with metastasis died so that the exact incidence of secondary tumors pathologically was too difficult to be known. The secondary tumors of heart usually come from the adjacent organs or tissues, which is commonly pulmonary carcinoma, esophageal carcinoma and malignant tumors of mediastinum. The case in the study was hepatocellular carcinoma which had invaded into the inferior vena cava and right atrium accompanying hemorrhagic hydro-pericardium confirmed by autopsy.

Diagnosis And Differential Diagnosis of Cardiac Tumor

Misdiagnosis often occurred because the incidence of cardiac tumors is very low and the early symptoms are not obvious and in late stage the symptoms and signs were indiscernible with those of other organic heart diseases. Of the cases in the study, 5 was misdiagnosed as mitral stenosis, 3 as common cold and rheumatic heart diseases respectively, 2 as anaemic heart diseases and constrictive pericarditis respectively, 1 as pneumonia, cor pulmonale, pulmonary tumor, cirrhosis of liver, psychoneurosis, hyperthyroidism, pleuritis, myocarditis, coronary heart disease, tuberculous pericarditis, pericardial cyst and fibrosarcoma respectively, and 2 as heart diseases in suspicion at first visit. The case of fibroma was misdiagnosed as mitral stenosis, and carried out mitral commissurotomy and later was rediagnosed as myxoma by echocardiogram. During the intracardiac surgery under extracorporeal circulation a year later, the tumor was found to increase a great deal and having involved the mitral valves, which was corrected as fibroma by pathologist. After operation the patient died of low cardiac output syndrome. The case of cyst-forming neurolemmafibrosarcoma was misdiagnosed as pericardial cyst and the case of pericardial malignant mesothelioma as tuberculous pericarditis. Hence they missed their therapeutic chances because the tumors were too large to be excised when operated.

The Differentiation of Myxomas with Organized Thrombi of Heart Should be Emphasized

The clinicopathological study of the 36 cases of myxoma showed the following differences:

1. Myxoma is commonly in the fossa ovalis of left atrium (91.7%) while the organized thrombus is commonly in the left auricle or other sites, usually accompanied with endocarditis, valvulopathy or myocardiosis, etc.

2. Myxoma is pleomorphic, smooth, light greyish red, semitransparent, tremelloid and brittle with a peduncle while the organized thrombus is usually oval, rough, dark red or greyish white, solid and maybe laminated without peduncle.

3. The cells of myxoma are distributed in the mucus-rich ground substance while the organized

thrombus may develop granulation tissues with mucus-free stroma.

Treatment And Prognosis of Cardiac Tumor

Cardiac tumors are different from others because even benign ones could cause fatal hemodynamic disturbance so that early diagnosis and operation are more important. The prognosis of the benign is good on the condition of early operation, but that of large and sessile ones is sometimes not good because of its extensive linking with heart.⁶ The case of fibroma couldn't be cured just because of its largeness even though the surgeons did their best to excise the tumor. The benign tumors were all cured although a case of myxoma was done a second excision after recurrence except that 5 cases of the benign in the study died of low cardiac output syndrome also because of their size, longer than 6 cm in diameter. The characteristics of the malignant tumors in the study is rapid growth, high invasiveness, marked atypia, all of which could make the prognosis worse, besides heart as a very special organ. One of the malignant tumors is pericardial malignant mesothelioma, 13×7×1.5 cm in size, which surrounded the heart and adhered to the pericardium extensively. Another is neurolemma-fibrosarcoma which grew rapidly to 18×12×10 cm only 3 months later after the emergence of the first symptom and was extensively adhered with pericardium, middle and inferior lobes of lungs and the venae cava. These two cases all missed the possibility of operation and biopsy is what could be

done in order to make a confirm diagnosis by pathologist. The third is hepatocellular carcinoma metastasized to the right atrium, confirmed by autopsy. All the cases of malignant tumors in the study died. Hence the prognosis of malignant cardiac tumors is worst.

REFERENCES

1. 刘万车. 心脏肿瘤. 白求恩医科大学学报 1983; 9(6): 98.
2. Fine G, Morales A, Horn RC. Cardiac Myxoma: A Morphologic and Histogenetic Appraisal. *Cancer* 1968; 22: 1156.
3. Feldman PS, Horvath E, Kovacs K. An Ultrastructural Study of Seven Cardiac Myxomas. *Cancer* 1977; 40(5): 2216.
4. 中华医学杂志编辑委员会. 心脏肿瘤专题座谈会纪要. *中华医学杂志* 1988; 68(12): 661.
5. Geha AS, Weidman WH, Soule EH, et al. Intramural Ventricular Cardiac Fibroma: Successful Removal in Two Cases and Review of the Literature. *Circulation* 1967; 36: 427.
6. Van Der Hauwaert LG, Corbeel L, Maldague P. Fibroma of The Right Ventricle Producing Severe Tricuspid Stenosis. *Circulation* 1965; 32: 451.
7. 王绪洲. 左心房巨大纤维瘤 1 例. *山东医药* 1992; 32(6): 62.
8. Bruni C, Prioleau PG, Hively T, et al. New Fine Structural Features of Cardiac Rhabdomyoma: Report of A Case. *Cancer* 1980; 46(9): 2068.