

Laparoscopic distal gastrectomy with D2 dissection for advanced gastric cancer

Jiang Yu, Yanfeng Hu, Tao Chen, Tingyu Mou, Xia Cheng, Guoxin Li

Department of General Surgery, Nanfang Hospital, Southern Medical University, Guangzhou 510515, China

Corresponding to: Guoxin Li. Department of General Surgery, Nanfang Hospital, Southern Medical University, Guangzhou 510515, China.

Email: gzliguoxin@163.com.

Abstract: The successful application of the laparoscopic distal gastrectomy with D2 dissection for gastric cancer requires adequate understanding of the anatomic characteristics of peripancreatic and intrathecal spaces, the role of pancreas and vascular bifurcation as the surgical landmarks, as well as the variations of gastric vascular anatomy. The standardized surgical procedures based on distribution of regional lymph node should be clarified.

Key Words: Gastric cancer; gastrectomy; laparoscopy



Submitted Jul 07, 2013. Accepted for publication Jul 12, 2013.

doi: 10.3978/j.issn.1000-9604.2013.08.09

Scan to your mobile device or view this article at: <http://www.thejcjr.org/article/view/2509/3418>

The D2 lymph node dissection has been widely applied in traditional open surgery for locally advanced gastric cancer with curative intent (1). However, the feasibility of this procedure in laparoscopic surgery has only been reported in a few conclusive studies around the world (2,3). That is because of the technical threshold for laparoscopic lymph node dissection derived from the perigastric anatomical complexity (4), which is an important factor of the surgical performance and the indicator of prognosis (5). Since the inception of this technique in our department in 2004, we have clinically accumulated proven experience in laparoscopic lymph node dissection for advanced gastric cancer. We believe that it is a combination of proper arrangement of surgical procedures and skilled application of laparoscopic techniques based on complete understanding of the perigastric space (6), surgical landmarks and variations in blood vessels.

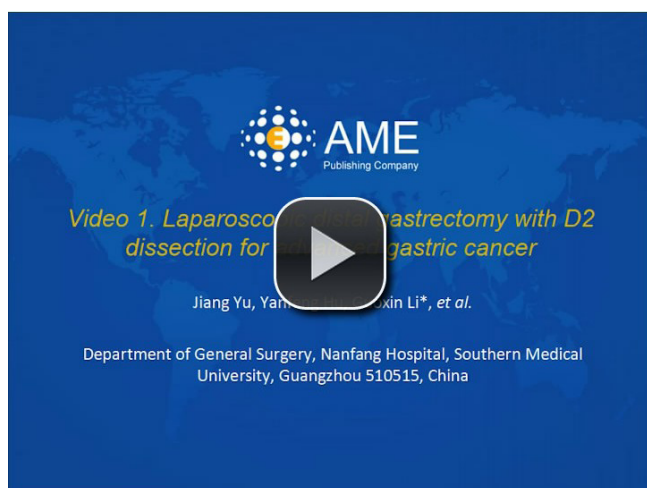
The key step in the radical treatment of distal gastric cancer lies in the regional lymph node dissection. The extent of D2 dissection for distal gastric cancer defined in the Japanese Gastric Cancer Surgery Guidelines and the Treatment Guideline for Gastric Cancer in Japan (7) involves stations number 1, 3, 4sb, 4d, 5, 6, 7, 8a, 9, 11p, 12a and 14v lymph nodes, while station 14v is excluded in

the latest guidelines.

According to the distribution of perigastric lymph nodes and the characteristics of laparoscopic techniques, especially the perigastric anatomical features of the gastric body and antrum flipped towards the head under laparoscopy, the scope of D2 lymph nodes can be divided into five regions: (I) lower left region (stations number 4sb and 4d around the left gastroepiploic vessel); (II) lower right region (mainly including station number 6 inferior to the pylorus, and at the root of the right gastroepiploic artery; station number 14v around the superior mesenteric vein in the former version); (III) upper right region (station number 5 superior to the pylorus and number 12a in the hepatoduodenal ligament); (IV) central region posterior to the gastric body (stations number 7, 8a, 9 and 11p surrounding the celiac artery and along its three branches); and (V) hepatogastric region (stations number 1 and 3 along the lesser curvature).

Based on the above classification, we have established the standard procedure for laparoscopic D2 lymphadenectomy for distal gastric cancer in our department (*Video 1*):

(I) The left side of the gastrocolic ligament is dissected near the transverse colon through to the lower splenic pole and the pancreatic tail. The key steps include extending and stretching the attachment of the greater omentum to



Video 1 Laparoscopic distal gastrectomy with D2 dissection for advanced gastric cancer

the transverse colon tightly, and then separating from the greater sac into the anterior and posterior space of the transverse mesocolon near splenic flexure, until the lower edge of the tail of the pancreas is exposed;

(II) The origin of the left gastroepiploic vessels are ligated. The key steps include extending and stretching the gastrosplenic ligament and fending off the posterior wall of the gastric fundus to expose the splenic hilum and the tail of the pancreas, and thereby the pancreatic capsule can be flipped from the lower edge to the upper edge of its tail. During this process, the left gastroepiploic artery and vein are ligated at the roots near the upper edge of the pancreatic tail, and division is continued from the greater curvature towards distal gastric body. The goal is the dissection of stations number 4sb and 4d lymph nodes;

(III) The right side of the gastrocolic ligament is cut near the transverse ligament through to the hepatic flexure, the hepatic flexure of the colon is separated from the duodenal bulb and the surface of the pancreatic head. The key steps include cutting the mesogastrium and the mesocolon along the attachment line between the posterior wall of gastric antrum and mesocolon, and retracting the posterior wall of the sinus to the left anterior direction and the colon and its mesentery to the lower right direction to expose the underlying loose fusion fascial space. Take time to divide the vessels. In the process, the anatomical layer should be fully exposed to separate the right side of the transverse colon and its mesentery from the duodenal descending part, the surface of pancreatic head and the lower edge of pancreatic neck it

is attached to. In this way, the gastrocolic trunk (variations may be present in certain patients) formed by the right gastroepiploic vein, right colic vein and their confluence has been completely revealed;

(IV) The right gastroepiploic vessels are transected. The key steps include fully exposing the lower edge of the pancreatic neck, the pancreatic head and the duodenum, so that the right gastroepiploic vein can be transected above the point where the anterior superior pancreaticoduodenal vein joins. Using the pancreas as a starting point, the pancreatic capsule is lifted and the tissue is separated from the lower edge of the pancreas along the anterior pancreatic space on the surface of the pancreas towards the external superior region, until the origin of the right gastroepiploic artery from the gastroduodenal artery is reached. The right gastroepiploic artery is then cut. The posterior inferior wall of duodenal bulb is denuded near the surface of the pancreatic head along the anterior pancreatic space. The goal is the dissection of stations number 6 lymph nodes;

(V) The gastroduodenal artery is exposed and the right gastric artery is transected. The key steps include transecting the duodenum only after dissecting the tissue around the pancreatic head and the upper part of the pancreatic neck from inferior to superior along the gastroduodenal artery in the posterior region of the duodenal bulb on the surface of the pancreas and on the plane of the anterior pancreatic space, in which the bifurcation of the common hepatic artery is exposed at the upper edge of the pancreatic edge for the access to the inner layer of arterial sheath, and the proper hepatic artery is denuded along the adventitia through to hepatoduodenal ligament, where the right gastric artery is cut at its root. The goal is the dissection of stations number 12a and 5 lymph nodes;

(VI) The three branches of the celiac trunk are divided and the left gastric artery is transected. The key steps include stretching the left gastric vascular pedicle in the gastropancreatic fold and fending the gastric body towards the anterior superior region while pulling the pancreas downwards to fully expose the upper edge of the pancreas for access to the posterior pancreatic space. The three branches of the celiac trunk are denuded here and the left gastric artery is transected at the root. The division is continued upwards in the space until the crura of the diaphragm. The goal is dissection of stations number 7, 8a, 9 and 11p lymph nodes;

(VII) The hepatogastric ligament and the anterior lobe of the hepatoduodenal ligament are transected close to the

lower edge of the liver, and the right side of the cardia and the lesser curvature are fully separated. The key steps include retracting the liver upwards and the gastric downwards to stretch the hepatogastric ligament so that the hepatogastric ligament and the anterior lobe of the hepatoduodenal ligament can be transected and the division can continue towards the right to reach the anterior surface of the proper hepatic artery, which has been separated previously, and towards the left to reach the right side of the cardia, where the lesser curvature is fully divided and denuded. Stations number 1 and 3 lymph nodes are dissected;

(VIII) The distal subtotal gastrectomy, and reconstruction of the digestive tract were completed through minilaparotomy.

The above surgical procedure is designed to accommodate the characteristics of laparoscopic techniques by organizing the sequence of operations from proximal to distal, inferior to superior, and posterior to anterior. More importantly, it has incorporated with our understanding of the anatomical structures under laparoscopy, so that we can make full use of the advantages of visual amplification to identify the relevant anatomical landmarks based on the shape, color and other features, and always proceed at the correct surgical plane while minimizing bleeding.

Acknowledgements

Disclosure: The authors declare no conflict of interest.

Cite this article as: Yu J, Hu Y, Chen T, Mou T, Cheng X, Li G. Laparoscopic distal gastrectomy with D2 dissection for advanced gastric cancer. *Chin J Cancer Res* 2013;25(4):474-476. doi: 10.3978/j.issn.1000-9604.2013.08.09

References

1. Song KY, Kim SN, Park CH. Laparoscopy-assisted distal gastrectomy with D2 lymph node dissection for gastric cancer: technical and oncologic aspects. *Surg Endosc* 2008;22:655-9.
2. Kim MC, Kim KH, Kim HH, et al. Comparison of laparoscopy-assisted by conventional open distal gastrectomy and extraperigastric lymph node dissection in early gastric cancer. *J Surg Oncol* 2005;91:90-4.
3. Hiroyuki Y, Mikito I, Mikiko H, et al. Current status and evaluation of laparoscopic surgery for gastric cancer. *Digest Endosc* 2008;20:1-5.
4. Noshiro H, Nagai E, Shimizu S, et al. Laparoscopically assisted distal gastrectomy with standard radical lymph node dissection for gastric cancer. *Surg Endosc* 2005;19:1592-6.
5. Marchet A, Mocellin S, Ambrosi A, et al. The prognostic value of N-ratio in patients with gastric cancer: validation in a large, multicenter series. *Eur J Surg Oncol* 2008;34:159-65.
6. Li GX, Zhang C, Yu J. Laparoscopic distal gastrectomy with D2 dissection: based on the art of anatomy. *Journal of Surgery Concepts & Practice* 2007;12:523-7.
7. Japanese Gastric Cancer Association. Japanese Classification of Gastric Carcinoma - 2nd English Edition. *Gastric Cancer* 1998;1:10-24.