

Embolization of symptomatic renal angiomyolipoma with a mixture of lipiodol and PVA, a mid-term result

Qiang Huang, Ren-You Zhai

Department of Interventional Radiology, Beijing Chaoyang Hospital, Capital Medical University, Beijing 100020, China

Correspondence to: Qiang Huang. Department of Interventional Radiology, Beijing Chaoyang Hospital, Capital Medical University, No.8 Gongti South Road, Chaoyang District, Beijing 100020, China. Email: hq0713@163.com.

Objective: To evaluate the clinical effect of renal artery embolization with a mixture of lipiodol and polyvinyl alcohol (PVA) particles on symptomatic renal angiomyolipoma and to present the mid-term results from our single-center site.

Methods: We performed a retrospective review of the seven patients who underwent embolization with a mixture of lipiodol and PVA particles to treat symptomatic renal angiomyolipoma in our center between February 2011 and December 2013. Medical records and follow-up results were reviewed and analyzed.

Results: Seven patients underwent eight episodes of embolization using a mixture of lipiodol and PVA particles to treat symptomatic renal angiomyolipoma. One patient required a subsequent embolization of the right kidney 9 months after the initial embolization of the left kidney. No nephrectomy was required in any of these cases during follow-up. None had recurrence of tumor bleeding or rupture during follow-up. Decreased tumor size was achieved in six patients (85.7%) during the mid-term follow-up.

Conclusions: Embolization with a mixture of lipiodol and PVA particles is an effective and safe treatment for symptomatic renal angiomyolipoma. Based on the durable mid-term results of the present study, a mixture of lipiodol and PVA particles is recommended for embolization.

Keywords: Renal angiomyolipoma; embolization; lipiodol; polyvinyl alcohol (PVA)

Submitted Mar 21, 2014. Accepted for publication Jul 18, 2014.

doi: 10.3978/j.issn.1000-9604.2014.07.04

View this article at: <http://dx.doi.org/10.3978/j.issn.1000-9604.2014.07.04>

Introduction

Renal angiomyolipoma is an uncommon renal neoplasm that exhibits a benign course (1). Although more cases are incidentally identified because of the growing use of medical imaging, cases presenting with large-sized angiomyolipomas (greater than 4 cm), spontaneous hemorrhage or flank pain, which require invasive treatment, are still relatively rare (1). Surgical removal and embolization are the standard treatments for symptomatic angiomyolipoma; however, renal artery embolization has gained wider acceptance for its mini-invasiveness (1). There is no consensus on the embolization material. Polyvinyl alcohol (PVA) particles, absolute ethanol, coils, microcoils, and gelatin sponge have been successfully applied in the literature (2-7). Absolute ethanol has been widely accepted as a reliable

embolization material for renal angiomyolipoma (4,5,8,9). However, medical-grade absolute ethanol is not currently commercially available in China. Lipiodol is a conventional embolization agent used in the interventional treatment of hepatocellular carcinoma (10). Reports on lipiodol as an embolization material for renal angiomyolipoma are limited (8). Here, we present our experience of using a mixture of lipiodol and PVA particles as embolization materials to treat symptomatic renal angiomyolipoma.

Methods

Seven patients underwent embolization with a mixture of lipiodol and PVA particles to treat symptomatic renal angiomyolipoma and completed follow-up in our center between Feb 2011 and Dec 2013. All seven were included in

Table 1 Follow-up results after renal artery embolization for the treatment of renal angiomyolipoma

No	Renal function post-em within a week		Tumor size in CT (cm)	
	BUN (mmol/L)	CREA (μ mol/L)	Pre-em	Post-em [* , months]
1				
L	3.30	53.0	9.0	6.0 [13]
R	2.08	54.1	9.4	7.5 [5]
2	2.81	45.1	6.7	5.5 [19]
3	6.04	78.2	5.4	4.1 [4]
4	3.40	54.2	11.8	11.8 [3]
5	3.70	65.6	7.3	6.0 [7]
6	3.47	70.8	5.4	3.2 [18]
7	4.07	45.9	10.5	9.8 [8]

Pre-em, pre-embolization; Post-em, post-embolization; CT, computed tomography; BUN, blood urea nitrogen; CREA, creatinine. The normal range: BUN 2.85-7.14 mmol/L, and CREA 35-106 μ mol/L. *, duration between embolization and follow-up CT.

this study. Approval from the ethics committee in our center was waived for this retrospective study. Seven women with a mean age of 46 years, ranging from 25 to 77 years, were enrolled. The clinical presentation included flank pain and hematuria. One case presented with unstable hemodynamic state and required blood transfusion before emergency embolization was performed, while the other six were in stable condition with selective interventional treatment. Retroperitoneal hemorrhage was revealed by pre-operative computed tomography (CT) in two cases. The tumors were evaluated with CT before treatment in all cases. Tumor size was calculated as previously applied in the literature, and defined as the greatest cross-sectional dimension recorded on imaging at presentation (1,3,11).

Super-selective catheterization was performed using a co-axial micro-catheter system to embolize the tumor while sparing as much renal parenchyma as possible. A total of 10 mL of lipiodol and 1 mL (one bottle) of PVA particles (300-500 or 500-710 μ m, Cook, Bloomington, IN, USA) were sufficiently mixed by repeated extraction and injection using a 2-mL syringe. No contrast agent was added. The embolization mixture was made immediately after suitable super-selective catheterization was confirmed by angiography. The mixture was then injected with a 1-mL

syringe under fluoroscopic visualization. Embolization was terminated when a complete obliteration of the tumor vessels was confirmed by imaging.

Renal function tests, including blood urea nitrogen (BUN) and creatinine (CREA), were performed in all seven patients before and after the interventional procedures. Medical imaging follow-up was available in all cases. The tumor size was documented based on the maximal cross-sectional dimension, in contrast with the pre-operative images. The growth rate was calculated by comparing the change in diameter in the same cross-section of the lesion between the post- and pre-treatment images. Follow-up was completed by examining the medical record, during the outpatient service, and with a phone call.

Results

The pre-operative diagnosis was confirmed by CT in all the seven cases. Seven patients underwent eight episodes of embolization using a mixture of lipiodol and PVA particles to treat symptomatic renal angiomyolipoma. One patient required a subsequent embolization of the right kidney 9 months after the initial embolization of the left kidney. Post-embolization complaints of nausea, low-grade fever and/or flank pain occurred in two cases and were successfully mitigated with medical treatment. In our series, the pre- and post-embolization (within a week after embolization) renal function tests were all within normal range (BUN 2.85-7.14 mmol/L, and CREA 35-106 μ mol/L) (Table 1).

Clinical follow-up was available for all 7 patients, with a median duration of 21 months (range from 12 to 34 months). Six patients remained symptom-free during follow-up, while 1 complained of persistent mild flank pain that was less severe than pre-embolization levels, and further treatment was declined. No nephrectomy was required in any of the cases during follow-up. None had recurrence of tumor hemorrhaging or rupture during the follow-up. The tumor size was not obviously changed during the follow-up in one patient. A decrease in tumor size was achieved in the other six patients (85.7%) (Figure 1).

The median tumor size before renal artery embolization was 8.1 cm (range, 5.4-11.8 cm), while the mean size post-embolization was 6.7 cm (range, 3.2-11.8 cm). Therefore, after a median follow-up of 21 months, there was a mean decrease in tumor size of approximately 17.3% in our series (Table 1).

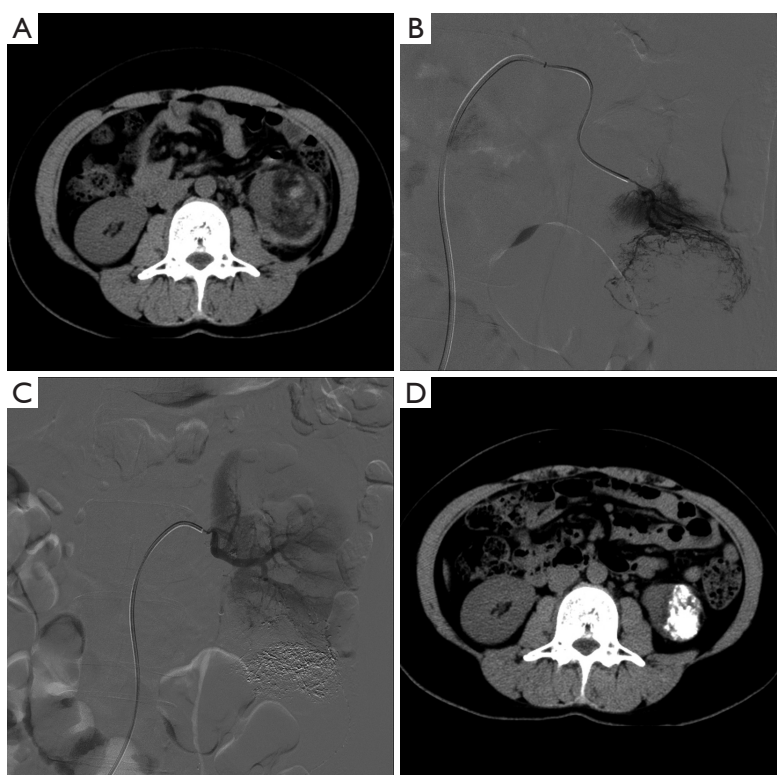


Figure 1 Renal angiomyolipoma embolized with a mixture of lipiodol and PVA in a 33-year-old female who presented with hematuria. (A) Pre-operative CT shows renal angiomyolipoma with hemorrhage in the lower pole of the left kidney; (B) angiogram demonstrates abnormal vascularity in the lower pole; (C) post-embolization angiography shows the lipiodol remaining in the lesion and the abnormal vascularity was eliminated; (D) CT obtained three months after embolization reveals lipiodol retained in the shrinking tumor. PVA, polyvinyl alcohol; CT, computed tomography.

Discussion

Renal angiomyolipoma is a common benign tumor composed of three tissue components: blood vessels, smooth muscle and adipose cells (2,6,8). It is classically identified by the presence of fat on CT, MRI, or ultrasonography (2,7,12). Angiomyolipomas greater than 4 cm are prone to spontaneous hemorrhagic rupture due to the abnormal, thick-walled vessels (3,4,13). Renal embolization has proved to be an effective treatment for renal angiomyolipoma for different purposes, namely for the acute management of tumor bleeding, prophylaxis of high-risk tumor, and pre-operative adjuncts for surgery (3).

Active surveillance of angiomyolipoma is a reasonable approach to the initial treatment of the disease, because of the slow growth rate and uncomplicated course of management (1). When invasive treatments are needed, renal conservation is vital regardless of the difference in treatment options (2,5). Embolization has a major advantage

over surgery, because functional renal tissue is spared as much as possible (2). Embolization is obviously minimally-invasive compared to surgery. Renal function can be reliably protected through super-selective catheterization, as proven by the results of our study.

Absolute ethanol is a cheap and effective embolization material for renal angiomyolipoma, with or without other materials, such as lipiodol and PVA particles (4,5,8,9). Absolute ethanol is superior to other materials because of its liquidity and high occlusion potential (4); however, medical absolute ethanol is not currently commercially available in China. The use of metallic coils should be limited to embolization at the site of the aneurysm rupture according to Katada *et al.* (14). Coils have only been used after a vascular bed was embolized and stasis was achieved (4), and in our center, they were only used in patients diagnosed with renal carcinoma or pre-operative embolization before definite surgical treatment.

To ensure the safety of embolization, using adequate and

appropriate embolization material is key. Because lipiodol can be seen under fluoroscopic guidance, it is an optimal choice as an embolization material. Lipiodol is the gold standard agent widely used in the embolization or chemo-embolization of hepatocellular carcinoma (10). However, there were only a few reports on the usage of lipiodol as an adjunct embolization material for renal angiomyolipoma (8).

Embolization of the tumor vasculature and the attempt to conserve normal renal parenchyma to the greatest extent possible not only provides hemostasis but also results in a reduction in the tumor diameter and conservation of renal function (14). Therefore, super-selective embolization should be performed with a co-axial micro-catheter system to spare as much renal parenchyma as possible. Because obliteration of the angiogenic component of the tumor is paramount for the treatment of renal angiomyolipoma, injecting lipiodol (mixed with PVA particles) under fluoroscopic guidance is reliable and safe to prevent reflux and non-target embolization. Lipiodol is visible under fluoroscopy, in contrast with other materials for the occlusion of the arteries at a capillary level. Follow-up with later medical imaging (especially CT) is also intuitive and convenient because lipiodol remained in the tumor for an extensive time. PVA particles are invisible under fluoroscopy and are often used with contrast agents. Here, PVA particles were applied with lipiodol to achieve more reliable occlusions of the tumor vessels. The durable embolic effect of the mixture of lipiodol and PVA was demonstrated by the mean shrinkage of the tumor size of approximately 17.3% in our series.

The main limitation of our study was the small size of the study group due to the rarity of symptomatic renal angiomyolipoma. However, the mixture of PVA and lipiodol has been demonstrated to provide durable mid-term results in our study. Only one patient had no obvious shrinkage in tumor size following embolization with the combination of lipiodol and PVA particles in our series.

Conclusions

In conclusion, renal artery embolization with a mixture of lipiodol and PVA particles is an effective and safe treatment for symptomatic renal angiomyolipoma. From these durable mid-term results, a mixture of lipiodol and PVA particles is a reliable material for embolization.

Acknowledgements

The assistance of technician Shi-Long Zhang and nurse

Hui-Ling Han is appreciated.

Disclosure: The authors declare no conflict of interest.

References

1. Mues AC, Palacios JM, Haramis G, et al. Contemporary experience in the management of angiomyolipoma. *J Endourol* 2010;24:1883-6.
2. Lenton J, Kessel D, Watkinson AF. Embolization of renal angiomyolipoma: immediate complications and long-term outcomes. *Clin Radiol* 2008;63:864-70.
3. Lee SY, Hsu HH, Chen YC, et al. Embolization of renal angiomyolipomas: short-term and long-term outcomes, complications, and tumor shrinkage. *Cardiovasc Intervent Radiol* 2009;32:1171-8.
4. Rimon U, Duvdevani M, Garniek A, et al. Ethanol and polyvinyl alcohol mixture for transcatheter embolization of renal angiomyolipoma. *AJR Am J Roentgenol* 2006;187:762-8.
5. Baba Y, Hayashi S, Ikeda S, et al. Evaluation of split renal function before and after renal arterial embolization for angiomyolipoma using absolute ethanol. *Cardiovasc Intervent Radiol* 2013. [Epub ahead of print].
6. Chan CK, Yu S, Yip S, et al. The efficacy, safety and durability of selective renal arterial embolization in treating symptomatic and asymptomatic renal angiomyolipoma. *Urology* 2011;77:642-8.
7. Halpenny D, Snow A, McNeill G, et al. The radiological diagnosis and treatment of renal angiomyolipoma-current status. *Clin Radiol* 2010;65:99-108.
8. Chick CM, Tan BS, Cheng C, et al. Long-term follow-up of the treatment of renal angiomyolipomas after selective arterial embolization with alcohol. *BJU Int* 2010;105:390-4.
9. Ramon J, Rimon U, Garniek A, et al. Renal angiomyolipoma: long-term results following selective arterial embolization. *Eur Urol* 2009;55:1155-61.
10. Idée JM, Guiu B. Use of Lipiodol as a drug-delivery system for transcatheter arterial chemoembolization of hepatocellular carcinoma: a review. *Crit Rev Oncol Hematol* 2013;88:530-49.
11. Seyam RM, Bissada NK, Kattan SA, et al. Changing trends in presentation, diagnosis and management of renal angiomyolipoma: comparison of sporadic and tuberous sclerosis complex-associated forms. *Urology* 2008;72:1077-82.
12. Abrams J, Yee DC, Clark TW. Transradial embolization of a bleeding renal angiomyolipoma. *Vasc Endovascular Surg*

- 2011;45:470-3.
13. Urciuoli P, D'Orazi V, Livadoti G, et al. Treatment of renal angiomyolipoma: surgery versus angioembolization. *G Chir* 2013;34:326-31.
 14. Katada Y, Umehara I, Ohki T, et al. Bilateral renal

angiomyolipoma in a patient with tuberous sclerosis treated with resection of one kidney and transarterial embolization of other kidney using CT during selective arteriography: a case report. *Cases J* 2009;2:6351.

Cite this article as: Huang Q, Zhai RY. Embolization of symptomatic renal angiomyolipoma with a mixture of lipiodol and PVA, a mid-term result. *Chin J Cancer Res* 2014;26(4):399-403. doi: 10.3978/j.issn.1000-9604.2014.07.04