

**Original Article****Anorectal Malignant Melanoma: Diagnosis and Treatment of 42 Cases**Xiao-bin Li<sup>1</sup>, Lin Shi<sup>2</sup>, Shuang-min Zhang<sup>1\*</sup><sup>1</sup>Department of General Surgery, Peking Union Medical College Hospital, Peking Union Medical College, Chinese Academy of Medical Sciences, Beijing 100730, China<sup>2</sup>Department of General Surgery, Haidian Hospital, Beijing 100080, China**CLC number: R735.3<sup>+</sup>8 Document code: A Article ID: 1000-9604(2010)03-0176-05****DOI: 10.1007/s11670-010-0176-7**

© Chinese Anti-Cancer Association and Springer-Verlag Berlin Heidelberg 2010

**ABSTRACT**

**Objective:** Anorectal malignant melanoma (AMM) is a rare and aggressive malignant tumor, and its treatment still controversial. This study was to investigate and summarize our experience on diagnosis, treatment and misdiagnosis of AMM.

**Methods:** From August 1980 to December 2009, 42 patients with AMM were treated in our hospital. The clinical data of those patients were retrospectively analyzed, including the major symptoms, treatment and prognosis. Further immunophenotyping analyses using antibodies to S-100 protein, HMB-45 reactive antigen and vimentin were performed in 22 specimens.

**Results:** The major complaints among the 42 cases were hematochezia (23/42, 55.0%), anal masses (12/42, 28.6%), changes in stool character (4/42, 9.5%), and anal tenesmus or pain (3/42, 7.1%). The misdiagnosis rate was 62% (26/42), the most common misdiagnosis consisted of hemorrhoid (9/26, 34.6%), polyps (11/26, 42.3%) and rectal cancer (6/26, 23.1%). 28 cases underwent abdominoperineal resection, 10 underwent local wide excision, 3 underwent palliative operation, and 1 with no operation. After surgery, 15 patients underwent radiotherapy, 21 underwent chemotherapy and 8 were treated with both. 22 cases deceased within 1 year, 11 within 2 years, 5 within 3 years and 1 within 4 years. The median survival time was 11 months, with the longest of 45 months. The immunohistochemical findings revealed that the S-100 protein was present in all 22 cases (100%), HMB-45 was stained in 19 of 22 (86.4%) and vimentin in 21 of 22 (95.5%).

**Conclusion:** AMM is a rare disease with a poor prognosis and with an aptitude of being misdiagnosed. Hematochezia is the most common symptom. Immunohistochemical staining is conducive to the diagnosis of AMM. Operation is the major treatment, the operation type should be individualized.

**Key words: Anorectal; Melanoma; Diagnosis; Treatment****INTRODUCTION**

Anorectal malignant melanoma (AMM) is a kind of rare malignant tumors, which is most commonly seen in the anal canal and rectum, accounting for about 1% of the anorectal malignant tumors<sup>[1-3]</sup>. Since Moore first described anorectal melanoma in 1857, less than 600 cases of AMM have been reported so far. Following head and neck

and the female genitourinary system, anorectum is the third most common site, accounting for 0.4% to 1.6% of all mucosal melanomas<sup>[4, 5]</sup>. AMM, featured by a high malignancy which leads to poor prognosis, is not distinctive in clinical manifestation<sup>[6]</sup>. Therefore, AMM is easily misdiagnosed, resulting in the belated treatment. Up to 60% of patients have metastatic disease at the time of diagnosis<sup>[7]</sup>. In this study, we retrospectively analyzed the medical records of 42 patients with AMM treated in Peking Union Medical College Hospital between 1980 and 2009. The results are shown as follows.

Received 2010-02-23; Accepted 2010-06-02

\*Corresponding author.

E-mail: zhangshuangmin000@sina.com

## MATERIALS AND METHODS

### General Data

From August 1980 to December 2009, a total of 42 cases including 15 males and 27 females with anorectal malignant melanoma were treated in our hospital, with their age ranged from 34 to 83 years. The average age was 62 years. The major symptoms were hematochezia (23/42, 55.0%), anal masses (12/42, 28.6%), changes in stool character (4/42, 9.5%), and anal tenesmus or pain (3/42, 7.1%). Digital examination of rectum and enteroscopy found that the tumors were basically in the vicinity of the dentate line, with 34 cases less than 3 cm and 8 cases between 3 and 5 cm. The diameter of the tumors was found to be less than or equal to 2 cm in 31 cases, larger than 2 cm in 10 cases, and even larger than 5 cm in 1 case.

### Diagnosis

In this group of patients, all diagnoses were verified by tumor biopsies or surgical pathology. All tumor biopsies and samples from surgical removal were examined pathologically, while 22 samples performed further immunohistochemical analyses using antibodies to S-100 protein, HMB-45 reactive antigen and vimentin. The pathological diagnoses were confirmed by two pathologists.

### Treatment and Follow-up

Among these patients, 28 cases underwent abdominoperineal resection (Miles procedure), 10 underwent local wide excision, 3 underwent palliative sigmoidostomy, and 1 had no operation due to oldness and severe heart and lung diseases. After surgery, 15 patients underwent radiotherapy, 21 underwent chemotherapy and 8 were treated with both.

For these 42 patients, outpatient examinations, telephone interviews, or postal questionnaires were used for follow-ups.

### Statistical Analysis

SPSS 13.0 software was used to plot Kaplan-Meier survival curve.

## RESULTS

Before surgery, the misdiagnosis rate was 62%

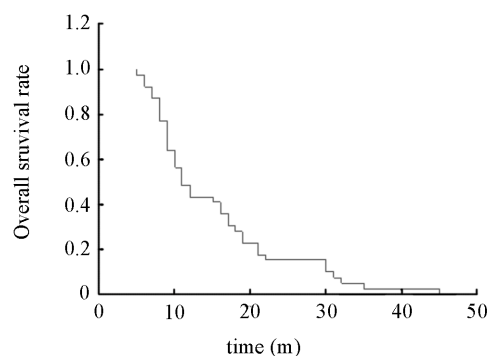


Figure 1. Kaplan-Meier survival curve.

Table 1. Immunohistochemical features of 22 cases of anorectal malignant melanoma

	Cases	-	+	++	+++	%
S-100	22	0	1	3	18	100%
HMB-45	22	3	4	2	13	86.4%
Vimentin	22	1	3	3	15	95.5%

-: no staining; +: <25% staining; ++: 25%–75% staining;  
 +++: >75% staining

(26/42), 9 patients were misdiagnosed as hemorrhoids (34.6%), 11 as polyps (42.3%), and 6 as rectal cancer (23.1%).

Confirmed by the post-operative pathological biopsy, the lesion of 20 cases was found to be limited within the submucosa, 16 cases invading the muscular layer, 5 cases invading the entire wall and serosa. 22 out of 28 patients that underwent abdominoperineal resection were found to have lymph node metastasis. 2 patients in the local excision group were performed abdominoperineal resection because of relapse.

The immunohistochemical findings revealed that the S-100 protein was present in all 22 cases (100%), HMB-45 was stained in 19 of 22 (86.4%) and vimentin in 21 of 22 (95.5%) (Table 1).

Among all the 42 patients, 22 cases deceased within 1 y, 11 within 2 y, 5 within 3 y and 1 within 4 y (45 m). The median survival time was 11 months (Figure 1). Three cases missed follow-up, yielding a follow-up rate of 93%.

## DISCUSSION

AMM is a rare disease with high malignancy.

Since the melanocytes abounded within the mucosa of the anal canal circle, most malignant melanocytes come from the anal canal, and a small number of it come from the lower rectum and the junction area of sigmoid colon and rectum. The rectal melanoma is derived from the melanoma cells in the rectal mucosa.

AMM is featured by its higher rate of misdiagnosis, which is about up to 80% in some foreign reports<sup>[1]</sup>. The same rate is also reported by some domestic findings. As a result of the misdiagnosis, 30%–60% of the patients are found lymphatic metastasis of varying extent. Misdiagnosis as hemorrhoids has a significant influence on the outcome of the patients especially<sup>[8, 9]</sup>. Therefore, it is of great importance to decrease the misdiagnosis rate in order to ameliorate the prognosis. Reasons that leads to high misdiagnosis rate of AMM might include the following: (1) The lacking of distinctive clinical manifestation, the common symptoms are hematochezia, anal masses, anal tenesmus or pain, changes in stool character, changes in the habits of defecation. The lesion is mostly in the vicinity of the dentate line, which is easily misdiagnosed as hemorrhoids, polyps of rectum, papilloma of anal canal, rectal cancer, and cancers of anal canals. (2) The diagnosis of AMM must be accompanied by pathological examinations. The tumor cells are easily mistaken for other tumors in that they are atypical and diversified. In the cytoplasm of some melanocytes, there is even no melanin. Therefore, the pathological confirmation might include immunohistochemical stain, including HMB45, S-100, and Vimentin tests to get a positive result<sup>[10]</sup>. (3) The low incidence of AMM leads to the scantiness of cognizance of the doctors. The misdiagnosis rate was 62% in this study cases before operation, 9 patients were misdiagnosed as hemorrhoids (34.6%), 11 as polyps (42.3%), and 6 as rectal cancer (23.1%). The scantiness of cognizance and no pathological examination were the main reasons of misdiagnosis as hemorrhoids and polyps. Misdiagnosis as rectal cancer was due to the less biopsy samples obtained and no immunohistochemical stain being done owing to the lacking of melanin granule in pathological examination.

Despite the lacking of distinction, there are several points that are conducive to early diagnosis. (1) It could occur at any age, more women were influenced than men. (2) The most commonly seen onset symptom is bloody stool, usually in bright red, mixed with a small amount of mucus, which is discrepant from the bloody stool of rectal cancer

that featured by a lot of mucus. It is also different from the bloody stool of hemorrhoids with almost no mucus. (3) The pain in anus in patients with AMM is often severer than rectal cancer. Other symptoms might be similar. (4) As a polypoid mass could be found in the digital examination. The stalk of the tumor should be short and wide. Some tumors are with black or brown pigmentation. So the doctors should focus on the history and symptoms to get primary differentiation. However, in some cases the lymphatic metastasis is found earlier than the primary lesion. The final diagnosis must be assisted by the histopathological examinations. Tumors with pigments are usually diagnosed with normal pathological examinations, while those without pigments need further immunohistochemical tests (HMB45, Vimentin and S-100 tests) for confirmation. Anti-S-100 protein is the most common screening immunohistochemical stain used in the diagnosis of malignant melanoma and is highly sensitive for melanocytic differentiation. A protein thought to affect intracellular trafficking of calcium, S-100 protein is present in many tissue types, including melanocytic proliferations, neuroendocrine cells, nerve sheath tumors, gliomas, and so on<sup>[11]</sup>. Given the lack of specificity, it is used primarily as a screening tool. In this case series, it was present in all 22 cases. HMB-45 is the most common “melanocyte-specific” stain used in the diagnosis of malignant melanoma. These monoclonal antibodies is specific for the inner membrane proteins present on premelanosomes and almost exclusively in cells that show some form of melanocytic differentiation. This stain is highly specific for melanocytes, but sensitivity is decreased compared with S-100 protein<sup>[11, 12]</sup>. In this series, HMB-45 reactive antigen was present in the majority of cases (86.4%). Vimentin was positive in all tumors, but it typically is uniformly present in malignant melanoma. Staining for vimentin in this series was present in the majority of cases (95.5%). In order to raise the definitive diagnosis rate and avert the iatrogenic spread, total tumor biopsy should be done as early as possible on suspected cases. It has been suggested that CT and MRI could provide important information for differentiation of AMM and other tumors<sup>[13]</sup>. The general types of AMM consist of nodular type, polyp type and ulcer type. Hematogenous metastasis is predominant, with its predilection site of liver, lung, brain and bones. Lymphatic metastasis is relatively less, with the metastasis sites of inguinal groove, obturator and the parailiac and paraaortic lymph nodes. Direct invasion is

relatively scarce, affecting mainly the pelvis, but the uterus and bladder are seldom influenced. Besides, even though the primary lesion is non-pigmental, the metastatic sites are usually black.

The prognosis of AMM is poor, and the 5-year survival rate is very low. Most of the patients die within 2 years. The median survival time is 18 months. Five-year survival rate is only about 10%<sup>[14, 15]</sup>. The best treatment is operation since the tumor is not sensitive to either radiotherapy or chemotherapy<sup>[16, 17]</sup>. However, the choice of operation, abdominoperineal resection or local wide excision, is still controversial in that the tumors locate in the recto-anal canal<sup>[18-20]</sup>. Some investigations found that the survival rate difference between the two operations were not significant, and therefore the local wide excision which retained the function of the anus and prevented the permanent colostomy should be favored<sup>[21]</sup>. Another viewpoint was that abdominoperineal resection could oppress the metastasis to the mesenteric lymph nodes. It was also considered to be more thorough in excision so that it had some advantages in controlling the relapse, especially for the early-stage patients<sup>[22]</sup>. Now it is generally considered that the operation type should be individualized<sup>[23]</sup>. The local wide excision should be the preferable treatment when the tumor is excisable. Abdominoperineal resection could be performed on those not suitable for local excision, recurring AMM or when tumor cell are found in the incision margin<sup>[24]</sup>. As for the patients with metastasis or suspected metastasis, dissection of inguinal lymph nodes is suggested. Preventive dissection of inguinal lymph nodes is not recommended. AMM is a relatively radiation insensitive tumour, but some anecdotal responses to treatment have been reported<sup>[25]</sup>. There are also individual case reports of successful palliation with intratumoral injections of interferon-beta in combination with chemotherapy in advanced anorectal melanoma<sup>[26]</sup>.

## REFERENCES

- [1] Pessaux P, Pocard M, Elias D, et al. Surgical management of primary anorectal melanoma[J]. *Br J Surg* 2004; 91:1183-7.
- [2] Thibault C, Sagar P, Nivatvongs S, et al. Anorectal melanoma--an incurable disease[J]? *Dis Colon Rectum* 1997; 40:661-8.
- [3] Chang AE, Karnell LH, Menck HR. The National Cancer Data Base report on cutaneous and non-cutaneous melanoma: a summary of 84,836 cases from the past decade. The American College of Surgeons Commission on Cancer and the American Cancer Society[J]. *Cancer* 1998; 83: 1664-78.
- [4] Mariolis-Sapsakos T, Malamitsi J, Yakoumakis E, et al. Is sentinel node mapping useful in anorectal melanoma[J]? *Hell J Nucl Med* 2008;11:39-42.
- [5] Tomacic J, Wanebo HJ. Mucosal melanomas[J]. *Surg Clin North Am* 2003; 83:237-52.
- [6] Khaled A, Hammami H, Fazaa B, et al. Primary amelanotic anorectal melanoma: an uncommon neoplasia with poor prognosis[J]. *Pathologica* 2009; 101:126-9.
- [7] Yap LB, Neary P. A comparison of wide local excision with abdominoperineal resection in anorectal melanoma[J]. *Melanoma Res* 2004; 14:147-50.
- [8] Winburn GB. Anal carcinoma or "just hemorrhoids"[J]? *Am Surg* 2001; 67:1048-58.
- [9] Sherwani RK, Kumar A, Raza MH. Haemorrhoids or anal melanoma, importance of preoperative histopathological examination: a case report[J]. *Pol J Pathol* 2010; 61:46-8.
- [10] Chute DJ, Cousar JB, Mills SE. Anorectal malignant melanoma morphologic and immunohistochemical features[J]. *Am J Clin Pathol* 2006; 126:93-100.
- [11] Kucher C, Zhang PJ, Acs G, et al. Can Melan-A replace S-100 and HMB-45 in the evaluation of sentinel lymph nodes from patients with malignant melanoma[J]? *Appl Immunohistochem Mol Morphol* 2006; 14:324-7.
- [12] Nakhleh RE, Wick MR, Rocamora A, et al. Morphologic diversity in malignant melanomas[J]. *Am J Clin Pathol* 1990; 93:731-40.
- [13] Filippone A, Ambrosini R, Fuschi M, et al. Preoperative T and N staging of colorectal cancer: accuracy of contrast-enhanced multi-detector row CT colonography--initial experience[J]. *Radiology* 2004; 231:83-90.
- [14] Maqbool A, Lintner R, Bokhari A, et al. Anorectal melanoma--3 case reports and a review of the literature [J]. *Cutis* 2004; 73:409-13.
- [15] Bullard KM, Tuttle TM, Rothenberger DA, et al. Surgical therapy for anorectal melanoma[J]. *J Am Coll Surg* 2003; 196:206-11.
- [16] Kim KB, Sanguino AM, Hodges C, et al. Biochemotherapy in patients with metastatic anorectal mucosal melanoma [J]. *Cancer* 2004; 100:1478-83.
- [17] Moozar KL, Wong CS, Couture J. Anorectal malignant melanoma: treatment with surgery or radiation therapy, or both[J]. *Can J Surg* 2003; 46:345-9.
- [18] Iddings DM, Fleisig AJ, Chen SL, et al. Practice patterns and outcomes for anorectal melanoma in the USA, reviewing three decades of treatment: is more extensive surgical resection beneficial in all patients[J]? *Ann Surg Oncol* 2010; 17:40-4.
- [19] Martínez-Hernández-Magro P, Villanueva-Sáenz E, Chávez-Colunga L. Anal malignant melanoma. Case report and literature review[J]. *Rev Gastroenterol Mex* 2009; 74:39-44.
- [20] Nilsson PJ, Ragnarsson-Olding BK. Importance of clear resection margins in anorectal malignant melanoma[J]. *Br J Surg* 2010; 97:98-103.
- [21] Droesch JT, Flum DR, Mann GN. Wide local

- excision or abdominoperineal resection as the initial treatment for anorectal melanoma[J]? *Am J Surg* 2005; 189:446–9.
- [22] Brady MS, Kavolius JP, Quan SH. Anorectal melanoma. A 64-year experience at Memorial Sloan-Kettering Cancer Center[J]. *Dis Colon Rectum* 1995; 38:146–51.
- [23] Ramakrishnan AS, Mahajan V, Kannan R. Optimizing local control in anorectal melanoma[J]. *Indian J Cancer* 2008; 45:13–9.
- [24] David AW, Perakath B. Management of anorectal melanomas: a 10-year review[J]. *Trop Gastroenterol* 2007; 28:76–8.
- [25] Pantalone D, Taruffi F, Paolucci R, et al. Malignant melanoma of the rectum[J]. *Eur J Surg* 2000; 166:583–4.
- [26] Ulmer A, Metzger S, Fierlbeck G. Successful palliation of stenosing anorectal melanoma by intratumoral injections with natural interferon-beta[J]. *Melanoma Res* 2002; 12:395–8.