

## ASSOCIATION OF EXPRESSION OF P53 PROTEIN WITH CELL PROLIFERATIVE ACTIVITY AND PROGNOSIS IN COLORECTAL CANCER

Gan Huatian 甘华田    Ouyang Qin 欧阳钦    Wang Yiping 王一平    Li Gandi 李甘地  
Ma Hongsheng 马洪升    Yang Zhengbing 杨正兵    Li Fengyua 李奉媛

*Department of Internal Medicine, The First Affiliated Hospital, West China University of Medical Sciences, Chengdu, 610041*

The expression of p53 protein in 66 cases of colorectal cancer and its relationship to cell proliferative activity, lymph node metastasis as well as prognosis were investigated by means of AB-PAP immunohistochemical technique. The results showed that 62.1% of colorectal cancer was positive of p53 expression. The cell proliferative activity and the frequency of lymph node metastasis in p53- positive tumors were significantly higher than those in p53-negative tumors ( $P<0.05$ ). The survival rate in patients with p53- positive tumors was significantly poorer than those with p53- negative tumors ( $P<0.05$ ). Our results suggest that the abnormal expression of p53 and cell proliferation associated with mutations are involved in both human carcinogenesis and lymph node metastasis of colorectal cancer. Examination of p53 expression is of value in understanding the degree of malignancy, and evaluating prognosis of the disease.

**Key Words:** Colorectal neoplasm, p53 Protein, Proliferative activity

p53 gene, one of well known tumor suppresser genes, has the cell-cycle negative regulating function and regulates cell proliferation.<sup>1,2</sup> The mutations and expression of p53 gene in colorectal cancer have been studied comprehensively, but few reports discussed the relationship of its expression to cell proliferative

activity, lymph node metastasis as well as prognosis of the disease. We hereby investigated expression of p53 protein and proliferating cell nuclear antigen (PCNA) in colorectal cancer with AB-PAP immunohistochemical technique to find out the correlation between p53 protein expression and cell proliferative activity and prognosis, and evaluate its clinical significance.

### MATERIALS AND METHODS

#### Samples

Sixty-six paraffin-embedded tissues of colorectal cancer (34 cases with lymphatic metastasis) selected from The Department of Pathology, The First Affiliated Hospital, West China University of Medical Sciences were investigated in our study. 11 normal colorectal mucosa were used as control.

#### Immunohistochemical Study

The immunohistochemical assay for expression of p53 protein and PCNA were performed by means of AB-PAP method as described by Davidoff, et al.<sup>3</sup> Anti-p53 protein monoclonal antibody Do-1 (1: 40) and anti-PCNA monoclonal antibody PC<sub>10</sub> (1: 50) were obtained from Santa Cruz Company and Zymed Laboratory respectively. ABC and PAP kits were from Dako Company. With each series of tests positive and

Accepted Jan 28, 1997

negative control were carried out. p53 staining and PCNA staining were considered positive only when definite reddish-brown staining of nuclei was identified. PCNA count was determined by calculating positive cells per 1,000 malignant cells under 40 × light microscope.<sup>4</sup>

### Statistical Analysis

Statistical analysis of data were performed by using chi-square or student's *t*-test. Kaplan-Meier survival curves were constructed using the statistical package and assessed using the Logrank test.

## RESULTS

### Expression of p53 Protein and PCNA in Colorectal cancer

Positive stainings for p53 protein were detected immunohistochemically in 41 out of 66 colorectal cancer (62.1%), which were confined to malignant nuclei, and no membranous and cytoplasmic staining were observed. There were no positive stainings in colorectal normal mucosa. PCNA positive stainings were confined to the nuclei too. PCNA positive cells were present in the lower two-thirds of the crypts in normal mucosa, whereas the positive cells spread diffusely along the glands, even arrived at the surface epithelium in colorectal cancer. The PCNA count was 23.9% ± 10.9% ( $\bar{x} \pm S$ ) for normal mucosa and 71.2% ± 20.5% ( $\bar{x} \pm S$ ) for colorectal cancer respectively.

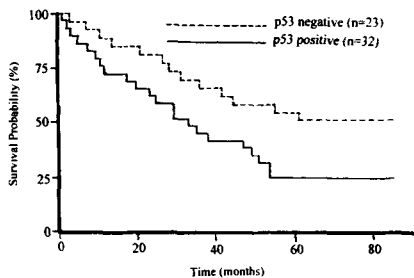


Fig 1. Kaplan-Meier Survival Curve

### The Relationship between Expression of p53 Protein and Cell Proliferative Activity

It is summarized in Table 1. PCNA count in p53-positive tumors was significantly higher than that in p53-negative tumors ( $P < 0.05$ ), indicating that there was a higher proliferative activity in p53-positive tumors.

Table 1. The relationship between p53 expression and PCNA count

p53 expression	No. of cases	PCNA count ( $\bar{x} \pm S$ )
Positive	41	78.2 ± 19.2*
Negative	25	61.3 ± 20.1

\*  $P < 0.05$

### The Relationship between Expression of p53 Protein, PCNA and Lymphatic Metastasis

It is presented in Table 2. The p53-positive rate and PCNA count in tumors with lymphatic metastasis were significantly higher than those without lymphatic metastasis. ( $P < 0.05$ ).

Table 2. The relationship between expression of p53, PCNA and lymphatic metastasis

Lymphatic metastasis	No. of cases	p53-positive rate(%)	PCNA count ( $\bar{x} \pm S$ )
Positive	34	25(73.5)*	76.8 ± 21.0*
Negative	32	16(50.0)	60.4 ± 20.7

\*  $P < 0.05$

### The Relationship between Expression of p53 Protein and the Survival of Cancer Patients

The follow-up was made in all cases and succeed in 55 cases (83.3%). Figure 1 shows the Kaplan-Meier survival curves for 55 patients. Patients with p53-positive tumors had a significantly worse survival rate than patients with p53-negative tumors. (logrank test,  $X^2 = 5.59$ ,  $P < 0.05$ ).

## DISCUSSION

In normal cells, wild-type p53 gene participates in the cell cycle regulation and inhibits the progression of cells from the G<sub>1</sub> to the S phase of cell cycle, playing negative regulatory role in the cell proliferation and differentiation.<sup>1</sup> It was therefore considered as a modulator of cell proliferation. Wild-type p53 gene

codes for a 53000 nuclear phosphoprotein with a short half-life, which is difficult to be demonstrated by immunohistochemical staining. Whereas the mutations of p53 gene result in a mutant p53 protein with a longer half-life, which could be detected by immunohistochemical method. So a positive result might imply the presence of mutant p53 gene.<sup>5</sup> In this study, we found the expression of p53 protein in 62.1% of colorectal cancer, suggesting that the mutations of p53 gene is an important genetic event in colorectal carcinogenesis.

To evaluate how is the cell proliferative activity as the mutations of p53 gene occurred, PCNA, a ideal marker for cell proliferation, was selected to assess the proliferative activity. PCNA (molecular weight, 36000) is a cell cycle-related nuclear protein that is elevated in late G<sub>1</sub>, reached a peak near the G<sub>1</sub>/S boundary and persisted at plateau in S stage.<sup>6</sup> The characterization of the marker indicate it's usefulness in the investigation of cell proliferative state while mutations of p53 gene occurred. Our results showed that cell proliferative activity in p53-positive tumors were significantly higher than that in p53-negative tumors. Similar results were reported by Yamaguchi, et al.<sup>5</sup> The results indicate that mutant p53 gene lack the ability of wild-type p53 gene to inhibit cell proliferation, which may confer malignant proliferation of cell. It has been well accepted that proliferative state of cancer cells is an important indicator of malignant degree. Therefore it may be concluded that p53-positive tumors with overexpression of PCNA indicate a higher malignant potential. So we think the combinative detection of p53 protein and PCNA expression is highly valuable in assessing the degree of tumor malignancy.

Our investigation also showed that expression of p53 protein was associated with lymphatic metastasis of tumors, suggesting the mutations of p53 gene in colorectal cancer were involved in both carcinogenesis and metastasis of lymph nodes. In addition, we also found that the proliferative activity in tumors with lymphatic metastasis was significantly higher than that without lymphatic metastasis, indicating that there were more opportunity for lymphatic metastasis in tumors with higher proliferative activity. Since lymphatic metastasis is a well known important indicator of poor prognosis in colorectal cancer, early knowing the tendency of lymphatic metastasis is

important in choosing an adequate therapeutic method and improving the prognosis. Our results provide a useful indicator to determine the possibility of lymphatic metastasis of the cancer.

Many recent data have demonstrated a close correlation between p53 protein expression and prognosis of several malignant tumors. Here, we also found that the survival rate in patients with p53-positive tumors was significantly poorer than those with p53-negative tumors. Yamaguchi, et al. thought this poor prognosis of patients with p53-positive tumor might be associated with a higher cell proliferative activity.<sup>5</sup> We therefore come to the conclusion that detection of p53 protein expression is valuable not only in understanding the degree of malignancy, but also in evaluating prognosis of colorectal cancer.

---

#### Acknowledgment

We are indebted to Professor Xia Ma for his help in statistical analysis of data.

#### REFERENCES

1. Ullrich SJ, Anderson CW, Edward Mercer WE, et al. The p53 tumor suppresser protein; a modulator of cell proliferation. *J Biol Chem* 1992; 267: 921.
2. Baker s, Markowitz S, Fearon E, et al. Suppressor of human colorectal carcinoma cell growth by wild-type p53. *Science* 1990; 249: 921.
3. Davidoff M, Schulze W. Combination of the peroxidase anti-peroxidase (PAP) and avidin-biothin-peroxidase complex (ABC) techniques: an amplification alternative in immunocytochemical staining. *Histochem* 1990; 93: 531.
4. Jain S, Fillipe MI, Hall PA, et al. Prognostic value of proliferating cell nuclear antigen in gastric carcinoma. *J Chin Pathol* 1991; 44: 665.
5. Yamaguchi A, Kurosaka Y, Fushida S, et al. Expression of p53 protein in colorectal cancer and its relationship to short-term prognosis. *Cancer* 1992; 70: 2778.
6. Robbinson BA, Vega DDL, Ogata K, et al. Immunohistochemical detection of proliferating cell nuclear antigen in solid human malignancies. *Arch Pathol Lab Med* 1987; 111:841.