

A CASE OF MESOTHELIOMA OF THE ATRIOVENTRICULAR NODE

Luo Bin 罗斌 Song Yixuan 宋一璇 Yao Qingsong 姚青松

The Department of Forensic Pathology, Sun Yat-sen University of Medical Sciences

The case, a 8-year-old boy, who died from traffic accident.

Grossly, the heart weights 115g and the inferior part of atrial septum is 3.6~4.0mm in thickness (1.8~2.0mm in thickness of this part in a normal heart). No other abnormalities were found in this heart.

Microscopically, the tumor is locates in right upper of atrioventricular node and 45 μ m apart from the node, and invades the intra-atrial bundle. The tumor is 1.6mm \times 4.8mm \times 2.9mm in size, which comprises nests, cords of cells which appear as solid consist of squamoid epithelia, basal cells and transparent cells. The majority of the cysts is lined frequently with multilayered cuboidal or squamous epithelia, while some cysts are lined occasionally by simple cuboidal or squamous epithelia, with intercellular bridge but without keratin pearl. Eosinophile staining and PAS positive material is present in lumina of some cysts which occasionally contain calcified bodies, epithelia and foamy phagocytes (Figure). The cells in the nests are often small, and their nuclei locate in the center without mitosis. Hyaline degenerated collagen fibers are abundant in the stroma. The tumor has no capsule membrane and infiltrates into surrounding tissue including atrial myocardium. But there is no atrophy or degeneration in this atrial myocardium.

DISCUSSION

Until 1977, there was little knowing about the histogenesis of the mesothelioma of the atrioventricular node and the nomenclature was in

confusion. Fenoglio¹ studied this tumor with ultrastructural method and revealed that the surface of the cells have numerous, widely spaced microvilli, and there are numerous intercellular spaces bound on all sides by tight junctions and desmosomes. The PAS positive material in the lumina of the cysts was also found. Fenoglio named this tumor as mesothelioma because all the findings are the features of mesothelial cell.

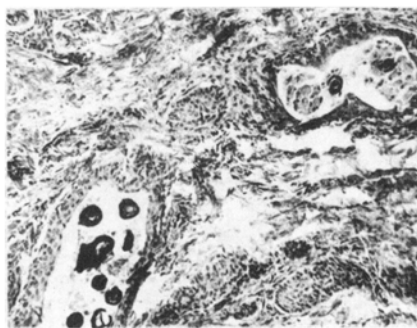


Fig. The cells lined by multilayered squamous epithelium. the calcified bodies and phagocytes in the mesothelioma of AVN.

Because the cells of this tumor have not the phenomenon of double-phase differentiated, and differ from that of mesothelioma derived from mesothelium of body cavities whereas they are histologically similar to adenomatoid tumor originated from testis and ovary, indicated that the tumor had a mesodermal origin. While the heart developing, a part of epithelium of body cavity is leaded into atrial septum, therefor generates tumors.

Burke² discovered that there were some argyrophile neuroendocrine cells among the CEA

positive cells arranging a tubular form in mesothelioma, and considered that this tumor originated from endodermal cells but not mesodermal cells.

As growing with age, the mesothelioma would invade atrioventricular node and cause partial or complete heart conducting block of which half of the patients die.

The calcified bodies emerging in the lumina of some cysts of mesothelioma were not mentioned in previous reports. In addition, the mesothelioma in this case was a poor differentiated tumor characterized by

a lot of nests and cords of cells while a few of high differentiated cystadenomatic cysts.

REFERENCES

1. Fenoglio J, et al. Ultrastructure of the mesothelioma of the atrio-ventricular node. *Cancer* 1977; 40: 721.
2. Burke M, et al. Tumor of the atrioventricular node region: a clinical and immunohistochemical study. *Arch Pathol Lab Med* 1990; 114: 1057.