

# Laparoscopy-assisted D2 radical distal gastrectomy for gastric cancer (Billroth II anastomosis)

Hanhui Yao, Qiang Huang, Zhiqiang Zhu, Wei Liang

Department of General Surgery, Anhui Provincial Hospital Affiliated to Anhui Medical University, Hefei 230001, China

Corresponding to: Hanhui Yao. Department of General Surgery, Anhui Provincial Hospital Affiliated to Anhui Medical University, Hefei 230001, China. Email: yaohanhui@aliyun.com.

**Abstract:** Laparoscopic radical gastrectomy has been increasingly applied in China. However, how to reduce surgery-related trauma, shorten operative time and achieve the long-term prognosis equal to the conventional open surgery is still hot research topics. Along with the change in learning curve and the optimization of endoscopic techniques, laparoscopic lymph node dissection can achieve or even exceed the extent that can be achieved in open surgery. Therefore, it has gradually replaced the conventional digestive tract reconstruction using an auxiliary incision. By completing the laparoscopic digestive tract reconstruction with EndoGIA, we describe the laparoscopy-assisted D2 radical distal gastrectomy for gastric cancer (Billroth II anastomosis).

**Key Words:** Laparoscope; radical gastrectomy; Billroth II anastomosis



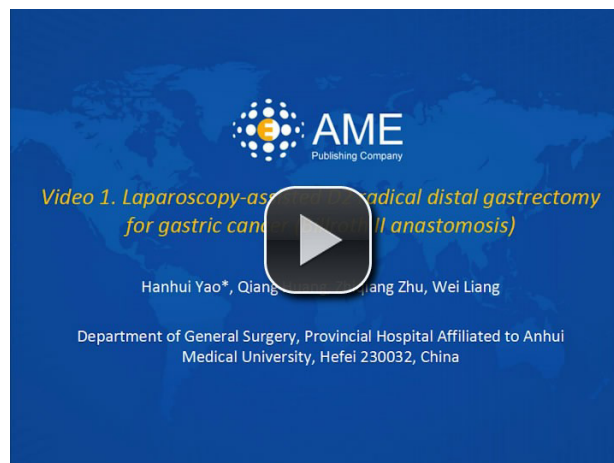
Submitted July 03, 2013. Accepted for publication July 19, 2013.

doi: 10.3978/j.issn.1000-9604.2013.07.02

Scan to your mobile device or view this article at: <http://www.thecjcr.org/article/view/2458/3409>

A 64-year-old female patient was admitted due to “upper abdominal discomfort accompanied with belching for half a year”. Gastroscopy confirmed the presence of adenocarcinoma of gastric antrum (moderately differentiated). No evidence of distant metastasis was found during the preoperative imaging. The preoperative TNM stage was T3N<sub>x</sub>M0.

During the surgery (*Video 1*), the patient was supine and in a split-legged position after endotracheal general anesthesia. The surgeon stood at the left side of the patient, the assistant at the right side of the patient, and the camera holder between her two legs. The CO<sub>2</sub> pneumoperitoneum was created, and its pressure was maintained at 12 mmHg. The umbilicus was used as the observation hole. Four ports were symmetrically established at the left and right sides of the axillary line and midclavicular line, with the port at the left side of the axillary line as the main working port. Abdominal exploration showed that the tumor was located in the gastric antrum and invaded the serosal layer, while no distant metastasis at liver or pelvic floor was found. The tumor surface was blocked with biological glue to avoid cell



**Video 1** Laparoscopy-assisted D2 radical distal gastrectomy for gastric cancer (Billroth II anastomosis)

shedding during the surgery.

After the greater omentum was flipped and raised by the assistant, the operator stretched the transverse colon and separated the gastrocolic ligament along the colon

attachment to enter the omental bursa. After the removal of greater omentum, the operation continued leftwards to the lower pole of the spleen and rightwards to the duodenum. The greater omentum was rolled under the liver, withdrawing the stomach towards the head side to expose the pancreas thoroughly. The pancreatic capsule was disassociated along the pancreatic upper space. Then, the splenic vein was exposed at the tail of the pancreas. Along the splenic vein, the tail of the pancreas was dissociated to expose the left gastroepiploic artery and the vessels at the lower splenic pole; meanwhile, the station N4sb lymph nodes were dissected. While the vessels to the lower splenic pole were preserved, the left gastroepiploic artery was transected. The gastric greater curvature was exposed downwards; meanwhile, the station N4d lymph nodes were dissected. Pancreatic head and loop of Henle were exposed between the two lobes of transverse mesocolon; meanwhile, the station N14v was explored to identify whether it had become swollen. The right gastroepiploic vein was found by “climbing” the pancreas; it was dissociated along the loop of Henle, and then transected. Meanwhile, the station N6 lymph nodes between the arteries and veins were dissected. After the gastric body was uplifted by the assistant, the pancreas was gently pressed by the operator to lift the pancreatic capsule and expose the common hepatic artery, splenic artery, and the root of left gastric artery; meanwhile, the stations N11p and N7 were dissected. After the left gastric artery and coronary vein were exposed and transected, the station N9 was dissected till the diaphragmatic crus. The station N8a was dissected along the common hepatic artery. The right gastric artery was exposed from the lower approach and then transected. After the assistant continued to pick on the gastric body, the operator divided the posterior lobe of the hepatogastric ligament along the lesser curvature of the stomach, so as to prepare for the dissection of stations N1 and N3. Thus, after the gastric body was pulled downwards, the assistant uplifted the left liver, and the operator transected the hepatogastric ligament via the upper gastric approach.

Since the right gastric artery and the proper liver artery had already been exposed via the lower gastric approach, the dissection of stations N12a and N5 became relatively easy. The anterior lobe of the hepatogastric ligament was divided along the lesser curvature of the stomach, and then the stations N1 and N3 were completely dissected. Thus, the D2 lymph node dissection was completed.

The duodenum was closed 2 cm below the pylorus using an endoscopic linear stapler (3.5 mm blue cartridge EndoGIA, Covidien) and then the stomach was transected. Using the green stapler cartridge (height: 4.8 mm), the operator clamped the gastric body 5 cm above the tumor and then transected it. Upon removal, the specimen was placed in an endobag and extracted. The tumor was carefully protected to avoid shedding. Holes were made in the residual greater curvature of stomach and in the jejunum 15 cm away from the ligament of Treitz, respectively. The EndoGIA™ Universal staplers were applied to complete the anastomosis between the residual stomach and the jejunum. The common openings were closed by EndoGIA system. The anastomosis was further sutured under laparoscope. The surgical wound and anastomosis were explored to identify any active bleeding. Thus, the reconstruction of the gastrointestinal tract was completed.

One drainage tube was placed in the right upper abdomen. After the laparoscope was removed, the puncture hole around the umbilicus was extended by 3 cm, and then the specimen was harvested.

The duration of operation was 190 min, and the intra-operative blood loss was about 100 mL. No blood was transfused during the surgery. The post-operative pathological stage was T3N2aM0. The first anal exhaust after surgery occurred 48 hours after surgery. Five days after the surgery, she began taking liquid diet. She recovered well and was smoothly discharged 7 days after surgery.

## Acknowledgements

*Disclosure:* The authors declare no conflict of interest.

**Cite this article as:** Yao H, Huang Q, Zhu Z, Liang W. Laparoscopy-assisted D2 radical distal gastrectomy for gastric cancer (Billroth II anastomosis). *Chin J Cancer Res* 2013;25(4):451-452. doi: 10.3978/j.issn.1000-9604.2013.07.02