

Safety and feasibility of video-assisted thoracoscopic surgery for stage IIIA lung cancer

Wenlong Shao^{1,2,3*}, Jun Liu^{1,2,3*}, Wehua Liang^{1,2,3}, Hanzhang Chen^{1,2,3}, Shuben Li^{1,2,3}, Weiqiang Yin^{1,2,3}, Xin Zhang^{1,2,3}, Jianxing He^{1,2,3}

¹Department of Thoracic Surgery, The First Affiliated Hospital of Guangzhou Medical University, Guangzhou 510120, China; ²Department of Thoracic Surgery, Guangzhou Institute of Respiratory Diseases, Guangzhou 510120, China; ³Key cite of National Clinical Research Center for Respiratory Diseases, Guangzhou 510120, China

*These authors contributed equally to this work.

Correspondence to: Professor Jianxing He, MD, PhD, FACS. Department of Cardiothoracic Surgery, The First Affiliated Hospital of Guangzhou Medical University, 151 Yanjiang Road, Guangzhou 510120, China. Email: drjianxing.he@gmail.com.

Objective: The current study was prospectively designed to explore the application of video-assisted thoracoscopic surgery (VATS) radical treatment for patients with stage IIIA lung cancer, with the primary endpoints being the safety and feasibility of this operation and the second endpoints being the survival and complications after the surgery.

Methods: A total of 51 patients with radiologically or mediastinoscopically confirmed stage IIIA lung cancer underwent VATS radical treatment, during which the standard pulmonary lobectomy and mediastinal lymph node dissection were performed after pre-operative assessment. The operative time, intraoperative blood loss/complications, postoperative recovery, postoperative complications, and lymph node dissection were recorded and analyzed. This study was regarded as successful if the surgical success rate reached 90% or higher.

Results: A total of 51 patients with non-small cell lung cancer (NSCLC) were enrolled in this study from March 2009 to February 2010. The median post-operative follow-up duration was 50.5 months. Of these 51 patients, 41 (80.4%) had N₂ lymph node metastases. All patients underwent the thoracoscopic surgeries, among whom 50 (98%) received pulmonary lobectomy and mediastinal lymph node dissection completely under the thoracoscope, 6 had their incisions extended to about 6 cm due to larger tumor sizes, and 1 had his surgery performed using a 12 cm small incision for handling the adhesions between lymph nodes and blood vessels. No patient was converted to conventional open thoracotomy. No perioperative death was noted. One patient received a second surgery on the second post-operative day due to large drainage (>1,000 mL), and the postoperative recovery was satisfactory. Up to 45 patients (88.2%) did not suffer from any perioperative complication, and 6 (11.8%) experienced one or more complications.

Conclusions: VATS radical treatment is a safe and feasible treatment for stage IIIA lung cancer.

Keywords: Lung cancer; video-assisted thoracoscopic surgery (VATS); systematic node dissection (SND)

Submitted Jul 05, 2014. Accepted for publication Aug 06, 2014.

doi: 10.3978/j.issn.1000-9604.2014.08.05

View this article at: <http://dx.doi.org/10.3978/j.issn.1000-9604.2014.08.05>

Introduction

Lung cancer remains the leading cause of cancer death throughout the world, and most lung cancers are diagnosed in advanced stages (1). While stage IIIA lung cancer accounts for a high proportion, its treatment remains controversial (2). The use of video-assisted thoracoscopic

surgery (VATS) for the treatment of lung cancer was first reported in 1992 (3-5). Compared with conventional thoracotomy, VATS is associated with smaller wounds, less postoperative pain, less damage to the chest muscle and respiratory function, lower postoperative levels of inflammatory factors in circulation related to injury, and

higher immunity (6-11). However, only limited literatures have reported the application of VATS lobectomy for the treatment of stages II and III lung cancers (12-15). The impact of VATS lobectomy on the long-term survival of patients with stage IIIA lung cancer remains unclear (16).

The purpose of this study is to examine the feasibility of video-assisted thoracoscopic surgery (VATS) major pulmonary resection with systematic node dissection (SND) for clinical stage IIIA non-small cell lung cancer. Success is defined as VATS major pulmonary resection with SND without conversion. If success rate over 90%, VATS major pulmonary resection with SND is considered as feasible procedures for clinical stage IIIA non-small cell lung cancer. This study had been approved by the Ethics Committee of First Affiliated Hospital of Guangzhou Medical University, and all patients signed the informed consents. The clinical trial registration number of this study was NCT00862004.

Patients and Methods

Subject enrollment

The inclusion criteria were as follows: Histologically confirmed non-small cell lung cancer (Squamous, adenosquamous, large cell, or poorly differentiated) Stage IIIA (T1-3, N2, M0): N2 disease confirmed by any of the following: Mediastinoscopy; Bronchoscopy with fine-needle aspiration or esophagoscopy; or PET scan; ECOG performance status 0-1; From March 2009 to February 2010, a total of 51 patients with pre-operatively diagnosed stage IIIA NSCLC underwent VATS. All the patients underwent the total resection of the primary tumors and the systematic lymphadenectomy completely under the thoracoscope. The post-operative TNM staging was based on the seventh edition of International Association for the Study of Lung Cancer (IASLC) staging criteria. The baseline characteristics, treatment details, clinopathological data, and postoperative outcomes were recorded and analyzed.

Pre-operative preparation

The pre-operative preparation included detailed history-taking and physical examination, chest radiographic examination, thoracic and upper abdominal CT examinations, brain CT or MRI, pulmonary function tests, arterial blood gas analysis, ventilation/perfusion scan, and electrocardiography. Patients at risk for myocardial

infarction also underwent echocardiography, thallium stress test, maximal oxygen uptake test, exercise test, and coronary angiography. Bronchoscopy was also performed before the surgery to clarify the stages of tumors inside the bronchi. If pre-operative CT showed lymph nodes sized >1.5 cm at the mediastinum or PET/CT depicted mediastinal lymph nodes, mediastinoscopy or ultrasound bronchoscopy was performed for lymph node biopsy. Patients with PET/CT-identified pathologically confirmed metastases were enrolled in this study. For patients with symptoms and abnormal blood flow underwent further bone scans. For patients whose pre-operative lung function tests showed that they could not tolerate total pneumonectomy but the tumors were adhered to the main blood vessels, pulmonary artery angiography and remodeling were performed. For patients at high risk, right heart catheterization was performed to rule out pulmonary hypertension and prevent total pneumonectomy.

Operation

The procedures of VATS lobectomy has been described (17), which was similar to that reported by Shigemura *et al.* (16). Briefly, it was a purely endoscopic technique, with the operation completed fully based on the images displayed on the monitor. The operation hole was not retracted and sized about 3-5 cm (mean: 3.5 cm). Systematic lymph node dissection was performed upon the completion of lobectomy.

Post-operative care and follow up

After surgery, patients were advised to receive four to six cycles of platinum-based adjuvant chemotherapy. For N2 patients who had completed a thorough mediastinal lymph node dissection, not conventional adjuvant radiotherapy was conducted. In the case of enlarged lymph nodes during the follow-up period, adjuvant radiotherapy would be used for these patients. Postoperative follow-up data were obtained through post-operative revisits, imaging, and cancer patient registry. The incidences of complications and the mortality during the hospital and surgeries were recorded for each patient. After the surgery, chest CT was routinely performed every three months within the first post-operative year and every six months one year later.

Statistical analysis

Continuous variables used in descriptive statistics are

Table 1 Baseline characteristics, pathologic data, and treatment-related factors among 51 patients

Features	(N=51)
Sex (Male)	35 (68.6%)
Age	56.7±10.9
Tumor size	
≤2 cm	10 (20.0)
>2 cm, ≤3 cm	8 (16.0)
>3 cm, ≤5 cm	13 (26.0)
>5 cm, ≤7 cm	8 (16.0)
>7 cm	11 (22.0)
Pleural invasion (yes)	29 (56.9%)
T stage	
1a	6 (11.8)
1b	3 (5.9)
2a	1 (2.0)
2b	17 (33.3)
3	6 (11.8)
4	16 (31.4)
N stage	
0	1 (2.0)
1	9 (17.6)
2	41 (80.4)
FEV1% (<70%)	1 (2.0)
Tumor location (central)	6 (11.8)
Minimally invasive surgical procedures	
VATS	44 (86.3)
VATS with a 7 cm incision	6 (11.8)
VATS with a 12 cm incision	1 (2.0)
Histology	
SC	12 (23.5)
AD	29 (56.9)
ADSC	5 (9.8)
others	5 (9.8)

FEV 1, forced expiratory volume in 1 second; VATS, video-assisted thoracoscopic surgery; SC, squamous cell carcinoma; AD, adenocarcinoma; ADSC, adenosquamous cell carcinoma.

presented as mean ± standard deviation, and categorical variables are presented using percentages. Statistical parameters included: age, gender, histological type, visceral pleura invasion, tumor size, lymph node metastasis, staging as per the 7th edition of TNM, and VATS lung resection

type. The outcome indicators included the total number of the collected lymph nodes and the number of lymph node stations. Survival rates were calculated using the Kaplan-Meier curves. The survival time was calculated from surgery as a starting point, until death caused by cancer as an end point. The significance level is 0.05. All the statistical analyses were performed in the SPSS 15.0 software package.

Results

Patients' characteristics

From March 2009 to February 2010, a total of 51 NSCLC patients who had undergone VATS pulmonary resection and met our inclusion criteria were enrolled in this study. The median follow-up period was 50.5 months. Of these 51 patients, 41 (80.4%) had N₂ lymph node metastases. Among them 44 (86.3%) received pulmonary lobectomy and mediastinal lymph node dissection completely under the thoracoscope, 6 had their incisions extended to about 7 cm due to larger tumor sizes, and 1 had his surgery performed using a 12 cm small incision for handling the adhesions between lymph nodes and blood vessels (*Table 1*). The number of intra-operative lymph node dissection was 22.5±12.9, and the number of stations was 5.0±1.6. No patient was converted to conventional open thoracotomy.

Complications and mortality

No intra-operative death was noted. One patient received a second surgery on the second post-operative day due to large drainage (>1,000 mL), and the postoperative recovery was satisfactory. In another patient whose daily drainage was larger than 500 mL, conservative treatment yielded satisfactory outcomes. Up to 45 patients (88.2%) did not suffer from any perioperative complication, and 6 (11.8%) experienced one or more complications (*Table 2*).

Overall survival

Among these patients, the average survival time was 44.0±2.6 months (median survival time could not be computed), and the 5-year survival rate was 51.1% (*Figure 1*).

Discussion

As a widely recognized technique, VATS lobectomy has been recommended by NCCN guidelines as the surgery

Table 2 Complications after VATS lung resection in 51 patients with stage IIIA NSCLC

Complications ^a	No. of patients (%)
None	45 (88.2)
Air leak (lasting ≥7 days)	2 (3.9)
Atrial fibrillation	2 (3.9)
Serous drainage (requiring drainage ≥7 days)	3 (5.9)
Pneumonia	1 (2.0)
Subcutaneous air (requiring reinsertion of chest tube or subcutaneous catheter)	1 (2.0)
Bleeding	1 (2.0)
Atelectasis	2 (3.9)

^a, Some patients had more than one complication; VATS, video-assisted thoracoscopic surgery; NSCLC, non-small cell lung cancer.

of choice for early NSCLC. Our center has applied the VATS techniques for the radical resection of lung cancer since 1994, among which the thoracoscope-assisted small-incision operation was applied for the angioplasties in trachea, bronchus, and lung; the patients' long-term survivals showed no significant difference when compared with the conventional open thoracotomy (18,19) However, the feasibility of surgical treatment for stage IIIA lung cancer with mediastinal lymph node metastasis (N2) remain controversial. Also, it is unclear whether the VATS technique can be applied for stage IIIA lung cancer with lymph node metastasis. McKenna *et al.* have successfully conducted VATS radical treatment for 1,100 patients with lung cancer (including post-operative pathologically confirmed stage IIIA lung cancer), without increase in complications (12). Watanabe *et al.* did a retrospective study aimed at determining the outcome of patients with cN0-pN2 NSCLC who underwent VATS major pulmonary resection with SND versus the outcome after major pulmonary resection with SND by open thoracotomy (15). It demonstrated that VATS major pulmonary resection with SND was a feasible approach to management of cN0-pN2 NSCLC without loss of curability. It was unnecessary to convert the VATS approach to thoracotomy in order to do SND even if pN2 disease is revealed during VATS major pulmonary resection. As part of multimodality therapeutic approaches, surgery offers a survival benefit for patients with resectable N2 NSCLC (17,20-24). Hennon *et al.* found that, when VATS was applied for the treatment of advanced

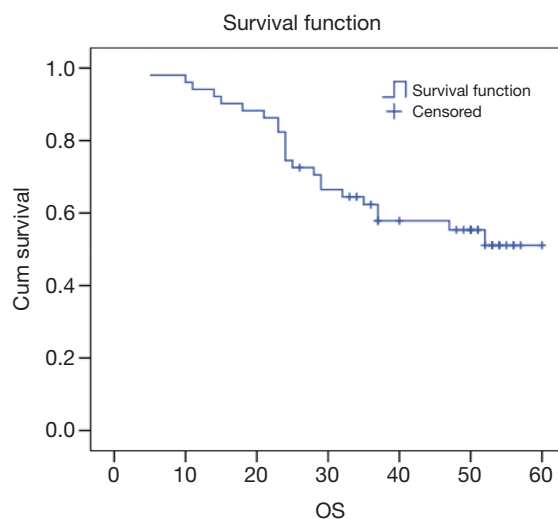


Figure 1 The survival curves of VATS for clinical resectable stage IIIA lung cancer. VATS, video-assisted thoracoscopic surgery.

lung cancer, it could smoothly and safely complete the expected tissue removal and lymphadenectomy (25). Our current study enrolled 51 patients with pre-operatively confirmed stage IIIA NSCLC, among whom the lobectomy and mediastinal lymph node dissection were successfully conducted. The intra-operative complications did not increase, and no patient was converted to conventional open thoracotomy. In a study with large sample size, after the surgery and multidisciplinary treatment for patients with stage IIIA NSCLC, the 5-year overall survival rates were 34.9% (26). In our cohort, the average survival time was (44.0±2.6) months, with the 5-year survival rate being 51.1%.

In conclusion, VATS radical treatment is a safe and feasible treatment for stage IIIA lung cancer.

Acknowledgements

Disclosure: The authors declare no conflict of interest.

References

1. Chen W, Zheng R, Zhang S, et al. Report of incidence and mortality in China cancer registries, 2009. *Chin J Cancer Res* 2013;25:10-21.
2. Goldstraw P. New TNM classification: achievements and hurdles. *Transl Lung Cancer Res* 2013;2:264-72.
3. Roviato G, Rebuffat C, Varoli F, et al. Videoendoscopic pulmonary lobectomy for cancer. *Surg Laparosc Endosc*

- 1992;2:244-7.
4. Landreneau RJ, Hazelrigg SR, Ferson PF, et al. Thoracoscopic resection of 85 pulmonary lesions. *Ann Thorac Surg* 1992;54:415-9; discussion 419-20.
 5. Lewis RJ, Sisler GE, Caccavale RJ. Imaged thoracic lobectomy: should it be done? *Ann Thorac Surg* 1992;54:80-3.
 6. Cao C, Manganas C, Ang SC, et al. A meta-analysis of unmatched and matched patients comparing video-assisted thoracoscopic lobectomy and conventional open lobectomy. *Ann Cardiothorac Surg* 2012;1:16-23.
 7. Lacin T, Swanson S. Current costs of video-assisted thoracic surgery (VATS) lobectomy. *J Thorac Dis* 2013;5:S190-3.
 8. Shimizu K, Okita R, Nakata M. Clinical significance of the tumor microenvironment in non-small cell lung cancer. *Ann Transl Med* 2013;1:20.
 9. Liang Y, Wakelee HA. Adjuvant chemotherapy of completely resected early stage non-small cell lung cancer (NSCLC). *Transl Lung Cancer* 2013;2:403-10.
 10. Bar J, Urban D, Borshtein R, et al. EGFR mutation in lung cancer: tumor heterogeneity and the impact of chemotherapy. *Chin Clin Oncol* 2013;2:2.
 11. Sim YT, Poon FW. Imaging of solitary pulmonary nodule—a clinical review. *Quant Imaging Med Surg* 2013;3:316-26.
 12. McKenna RJ Jr, Houck W, Fuller CB. Video-assisted thoracic surgery lobectomy: experience with 1,100 cases. *Ann Thorac Surg* 2006;81:421-5; discussion 425-6.
 13. Lewis RJ, Caccavale RJ, Sisler GE, et al. One hundred video-assisted thoracic surgical simultaneously stapled lobectomies without rib spreading. *Ann Thorac Surg* 1997;63:1415-21; discussion 1421-2.
 14. Mahtabifard A, Fuller CB, McKenna RJ Jr. Video-assisted thoracic surgery sleeve lobectomy: a case series. *Ann Thorac Surg* 2008;85:S729-32.
 15. Watanabe A, Ohori S, Nakashima S, et al. Feasibility of video-assisted thoracoscopic surgery segmentectomy for selected peripheral lung carcinomas. *Eur J Cardiothorac Surg* 2009;35:775-80; discussion 780.
 16. Shigemura N, Hsin MK, Yim AP. Segmental rib resection for difficult cases of video-assisted thoracic surgery. *J Thorac Cardiovasc Surg* 2006;132:701-2.
 17. He J, Yang Y, Chen M. Lobectomy by video-assisted thoracoscopic surgery. *Zhonghua Wai Ke Za Zhi* 1996;34:76-8.
 18. He J, Shao W, Cao C, et al. Long-term outcome and cost-effectiveness of complete versus assisted video-assisted thoracic surgery for non-small cell lung cancer. *J Surg Oncol* 2011;104:162-8.
 19. He J, Shao W, Cao C, et al. Long-term outcome of hybrid surgical approach of video-assisted minithoracotomy sleeve lobectomy for non-small-cell lung cancer. *Surg Endosc* 2011;25:2509-15.
 20. Watanabe A, Mishina T, Ohori S, et al. Is video-assisted thoracoscopic surgery a feasible approach for clinical N0 and postoperatively pathological N2 non-small cell lung cancer? *Eur J Cardiothorac Surg* 2008;33:812-8.
 21. Walker WS, Codispoti M, Soon SY, et al. Long-term outcomes following VATS lobectomy for non-small cell bronchogenic carcinoma. *Eur J Cardiothorac Surg* 2003;23:397-402.
 22. Roviario G, Varoli F, Vergani C, et al. Long-term survival after videothoracoscopic lobectomy for stage I lung cancer. *Chest* 2004;126:725-32.
 23. Congregado M, Merchan RJ, Gallardo G, et al. Video-assisted thoracic surgery (VATS) lobectomy: 13 years' experience. *Surg Endosc* 2008;22:1852-7.
 24. Bakir M, Fraser S, Routledge T, et al. Is surgery indicated in patients with stage IIIa lung cancer and mediastinal nodal involvement? *Interact Cardiovasc Thorac Surg* 2011;13:303-10.
 25. Hennon M, Sahai RK, Yendamuri S, et al. Safety of thoracoscopic lobectomy in locally advanced lung cancer. *Ann Surg Oncol* 2011;18:3732-6.
 26. Liang W, Shao W, Jiang G, et al. Chinese multi-institutional registry (CMIR) for resected non-small cell lung cancer: survival analysis of 5,853 cases. *J Thorac Dis* 2013;5:726-9.

Cite this article as: Shao W, Liu J, Liang W, Chen H, Li S, Yin W, Zhang X, He J. Safety and feasibility of video-assisted thoracoscopic surgery for stage IIIA lung cancer. *Chin J Cancer Res* 2014;26(4):418-422. doi: 10.3978/j.issn.1000-9604.2014.08.05